

## Radiosurgery in dentistry: a review

C. Lorenzi<sup>1</sup>, L. Arcuri<sup>1</sup>, F. Lio<sup>2</sup>, A. Dolci<sup>2</sup>, C. Arcuri<sup>2</sup>

<sup>1</sup>Department of Chemical Science and Technologies, University of Tor Vergata, Rome; <sup>2</sup>Department of Clinical Sciences and Translational Medicine, School of Dentistry, University of Tor Vergata, Rome, Italy

### Abstract

The aim of the present study was to analyse the clinical potential of radiosurgery applied to modern dentistry through a revision of the indexed literature.

Radiosurgery represents a recent form of electrosurgery working at a frequency of 3.0-4.0 MHz. The depth of penetration of the waves is inversely proportional to the frequency. Radiowaves working at high frequency express a lower penetration with a consequent lower tissue alteration. The authors analyzed the literature in order to give to the scientific community an overview of the possible applications of radiosurgery in the clinical dental practice and their effectiveness. Radiosurgery can be used in prosthodontics, in periodontal and implant surgery, in the treatment of trigeminal neuralgia, in the treatment of obstructive sleep apnea syndromes (OSAS) and in endodontics. Our analysis shows that although there are few articles in indexed literature on the applications of radiosurgery in dentistry, thanks to the benefits that derive from it, radiosurgery will spread more in the daily clinical practice of the dentists. *Clin Ter 2019; 170(1):e48-54. doi: 10.7417/CT.2019.2107*

**Key words:** dentistry, radiofrequency, radiosurgery, radio waves, electrosurgery

### Introduction

Radiosurgery is the term used to describe a particular form of electrosurgery. It operates within the frequency of 3.0 to 4.0 MHz.

The older electrosurgical instruments operated at lower frequencies of 1.0 MHz to 2.9 MHz.

The original electrosurgical equipment developed by Coles, Martin, and Ellman has been reduced with the development of more sophisticated waveforms and cutting tips. Dr. Irving Ellman developed the fully filtered waveform combined with a frequency of 3.8 MHz.

The term "radiosurgery" was coined by Dr. Goldstein to describe the 3.0 to 4.0 MHz radio wave device. He understood the need to differentiate the new, higher frequency

device that was able to produce less heat compared to the low-frequency, higher temperature electrosurgery machines (1).

Radio wave units operate on a 60-cycle alternating current that is converted to a direct current thanks to a rectifier. The direct current passes through a rectifier which generates radio waves (2). After that, these waves are passed through a wave form adapter that alters the intensity and characteristics of the radio waves generated. In this way, it is possible to attain the required waveform. Radio waves are transferred from the tip of an electrode and are returned to the unit by a neutral antenna plate. Resistance to the passage of radio waves through the tissues generates heat that is converted in tissue cutting or coagulation (3, 4). Heat diffusion also causes denaturation of intracellular proteins, noticeable as coagulative necrosis within a variable distance from the incision, known as "lateral thermal injury" (LTI) (5). The penetration depth of RF energy is inversely proportional to the frequency, so lower frequencies of RF penetrate more deeply (6).

In one study, Silverman et al. found that the penetration was significantly less (0.158 mm) with radiosurgery compared with CO2 laser (0.215 mm) (7).

High-frequency radiosurgery produces less tissue alteration and lateral heat to the surrounding tissues than the low-frequency electrosurgical signal (8).

Maness and his group showed that lower frequencies produce more lateral heat to the surrounding tissues and should be avoided when in close proximity to bone (9).

Incisions produced by radiosurgery are similar histologically to those produced by a scalpel because of the low level of thermal heat produced. The difference is that the scalpel requires pressure on incision with immediate bleeding and thus reduced surgical visibility (10).

With the radiosurgery the patient experiences a pressureless incision with a minimal amount of bleeding, which often requires no suturing and reduces bacteria, healing time, and discomfort.

There are different waveforms and the clinician has to choose the best one for the surgical objective.

Correspondence: Dr. Lorenzi, Via Cappuccini, 9 - 00037 Segni (Roma). E-mail: claudialorenzimartinez@gmail.com  
Dr. Arcuri L. E-mail: arcuri@med.uniroma2.it

The fully filtered and rectified waveform produces 10% coagulation and 90% cutting. It is a pure continuous flow of high-frequency energy. It resembles to a scalpel incision because of the continuous non pulsating current provided by the filter. This waveform is used for surgery near bone, frenulectomy, biopsy and mass removal.

The fully rectified waveform produces 50% coagulation and 50% cutting. This waveform can be used for gingivectomy, gingivoplasty, and for procedures of gingival displacement before prosthodontic impressions. It shouldn't be used for surgery near bone.

The partially rectified waveform produces 10% cutting and 90% coagulation with increased lateral heat and tissue contraction. It should not be used near bone.

The fulguration waveform uses a half-wave current for coagulation and tissue destruction. The electrode does not really touch tissue, but coagulates through energy transferred to tissue. This waveform is used for hemostasis near bone, destruction of fistulous tracts and removal of cyst remnants. The electrode used is positioned approximately 0.5 mm from the tissue surface (11).

Monopolar radiosurgery is used for cutting tissue with the use of a fine tungsten wire electrode. Bipolar surgery is used for excision and to establish hemostasis of soft tissue. The bipolar electrode consists of two parallel separate wires, one to make the incision and the other to act as the antenna to receive the RF energy. This configuration minimizes the chance of the heat to be absorbed by the surrounding tissues.

Bipolar radiosurgery has been recommended for exposition of an implant and for coagulation in the presence of an implant because the signal is absorbed by the adjacent electrode tip minimizing any heat transfer to the implant should the electrode inadvertently touch the implant (12).

Electrode tips:

- Diamond-shaped tips can be used for small biopsies. Only the lower third of the electrode should penetrate the tissue, creating a V-shaped incision.
- Larger-loop tips can be used for operculectomy and gingivectomy.
- Small elliptical loop tips can be used for crown-lengthening procedures and gingival contouring.
- Triangle-shaped tips can be used for gingivoplasty.
- The Vari-Tip electrode (Ellman, Oceanside, NY) can be used in many applications because it is adjustable.
- Pencil-point tips are used for fine coagulation.
- Ball-shaped tips can be used for gross coagulation.
- Fulgurating tips are used to destroy superficially tissue after biopsy, and to establish hemostasis during osseous surgery (11).

Radiosurgery has found several applications in clinical dentistry. There is a limited number of studies evaluating the applications of radio waves in dentistry. The aim of the present study is to analyze the indexed literature and to provide an update on the current applications of radiosurgery in dentistry.

## Materials and methods

We have formulated a specific question according to the Participants, Interventions, Control, and Outcomes (PICO) format. The question was: "What are the applications and advantages (O) of using radiosurgery (I) compared to traditional methods (C) in dental patients (P)?" The search strategy involved searching electronic databases: PubMed (National Library of Medicine), Google Scholar, Scopus, Embase, Medline, and Cochrane Library databases were searched without restrictions of time or idiom to find articles that described the basic principles of HRW and its applications in dental practice. The following combination of words was used: ("radiosurgery"[MeSH Terms] OR "radiosurgery"[All Fields]) OR ("radio waves"[MeSH Terms] OR ("radio"[All Fields] AND "waves"[All Fields]) OR "radio waves"[All Fields] OR ("radio"[All Fields] AND "wave"[All Fields]) OR "radio wave"[All Fields]) OR radio-frequency[All Fields] AND "Dentistry"[Mesh] OR# ("radiosurgery"[MeSH Terms] OR "radiosurgery"[All Fields]) OR ("radio waves"[MeSH Terms] OR ("radio"[All Fields] AND "waves"[All Fields]) OR "radio waves"[All Fields] OR ("radio"[All Fields] AND "wave"[All Fields]) OR "radio wave"[All Fields]) OR radio-frequency[All Fields] AND ("dental health services"[MeSH Terms] OR ("dental"[All Fields] AND "health"[All Fields] AND "services"[All Fields]) OR "dental health services"[All Fields] OR "dental"[All Fields]) OR# ("radiosurgery"[MeSH Terms] OR "radiosurgery"[All Fields]) OR ("radio waves"[MeSH Terms] OR ("radio"[All Fields] AND "waves"[All Fields]) OR "radio waves"[All Fields] OR radio-frequency[All Fields] AND ("mouth"[MeSH Terms] OR "mouth"[All Fields] OR "oral"[All Fields]) OR# ("radiosurgery"[MeSH Terms] OR "radiosurgery"[All Fields]) OR ("radio waves"[MeSH Terms] OR ("radio"[All Fields] AND "waves"[All Fields]) OR "radio waves"[All Fields]) OR radio-frequency[All Fields] AND ("prosthodontics"[MeSH Terms] OR "prosthodontics"[All Fields] OR ("prosthetic"[All Fields] AND "dentistry"[All Fields]) OR "prosthetic dentistry"[All Fields]) OR# ("radiosurgery"[MeSH Terms] OR "radiosurgery"[All Fields]) OR ("radio waves"[MeSH Terms] OR ("radio"[All Fields] AND "waves"[All Fields]) OR "radio waves"[All Fields]) OR radio-frequency[All Fields] AND ("dental implants"[MeSH Terms] OR ("dental"[All Fields] AND "implants"[All Fields]) OR "dental implants"[All Fields]) OR# ("radiosurgery"[MeSH Terms] OR "radiosurgery"[All Fields]) OR ("radio waves"[MeSH Terms] OR ("radio"[All Fields] AND "waves"[All Fields]) OR "radio waves"[All Fields]) OR radio-frequency[All Fields] AND ("endodontics"[MeSH Terms] OR "endodontics"[All Fields]) OR# ("radiosurgery"[MeSH Terms] OR "radiosurgery"[All Fields]) OR ("radio waves"[MeSH Terms] OR ("radio"[All Fields] AND "waves"[All Fields]) OR "radio waves"[All Fields]) OR radio-frequency[All Fields] AND ("sleep apnoea"[All Fields] OR "sleep apnea syndromes"[MeSH Terms] OR ("sleep"[All Fields] AND "apnea"[All Fields] AND "syndromes"[All Fields]) OR "sleep apnea syndromes"[All Fields] OR ("sleep"[All Fields] AND "apnea"[All Fields]) OR "sleep apnea"[All Fields]) OR# ("radiosurgery"[MeSH Terms] OR

“radiosurgery”[All Fields]) OR (“radio waves”[MeSH Terms] OR (“radio”[All Fields] AND “waves”[All Fields]) OR “radio waves”[All Fields]) OR radio-frequency[All Fields] AND (“trigeminal neuralgia”[MeSH Terms] OR (“trigeminal”[All Fields] AND “neuralgia”[All Fields]) OR “trigeminal neuralgia”[All Fields]) OR# (“radiosurgery”[MeSH Terms] OR “radiosurgery”[All Fields]) OR (“radio waves”[MeSH Terms] OR (“radio”[All Fields] AND “waves”[All Fields]) OR “radio waves”[All Fields]) OR radio-frequency[All Fields] AND (“periodontics”[MeSH Terms] OR “periodontics”[All Fields]) OR# (“radiosurgery”[MeSH Terms] OR “radiosurgery”[All Fields]) OR (“radio waves”[MeSH Terms] OR (“radio”[All Fields] AND “waves”[All Fields]) OR “radio waves”[All Fields]) OR radio-frequency[All Fields] AND (soft[All Fields] AND (“tissues”[MeSH Terms] OR “tissues”[All Fields])) OR# (“radiosurgery”[MeSH Terms] OR “radiosurgery”[All Fields]) OR (“radio waves”[MeSH Terms] OR (“radio”[All Fields] AND “waves”[All Fields]) OR “radio waves”[All Fields]) OR radio-frequency[All Fields] AND (“dental health services”[MeSH Terms] OR (“dental”[All Fields] AND “health”[All Fields] AND “services”[All Fields]) OR “dental health services”[All Fields] OR “dental”[All Fields]) AND (“surgery”[Subheading] OR “surgery”[All Fields] OR “surgical procedures, operative”[MeSH Terms] OR (“surgical”[All Fields] AND “procedures”[All Fields] AND “operative”[All Fields]) OR “operative surgical procedures”[All Fields] OR “surgery”[All Fields] OR “general surgery”[MeSH Terms] OR (“general”[All Fields] AND “surgery”[All Fields]) OR “general surgery”[All Fields])) We included all levels of available evidence (including case reports, in-vitro studies, studies in animal models, and case series). Commentaries, and letters to the editor were not sought.

## Results

### *Radiosurgery and dental impressions*

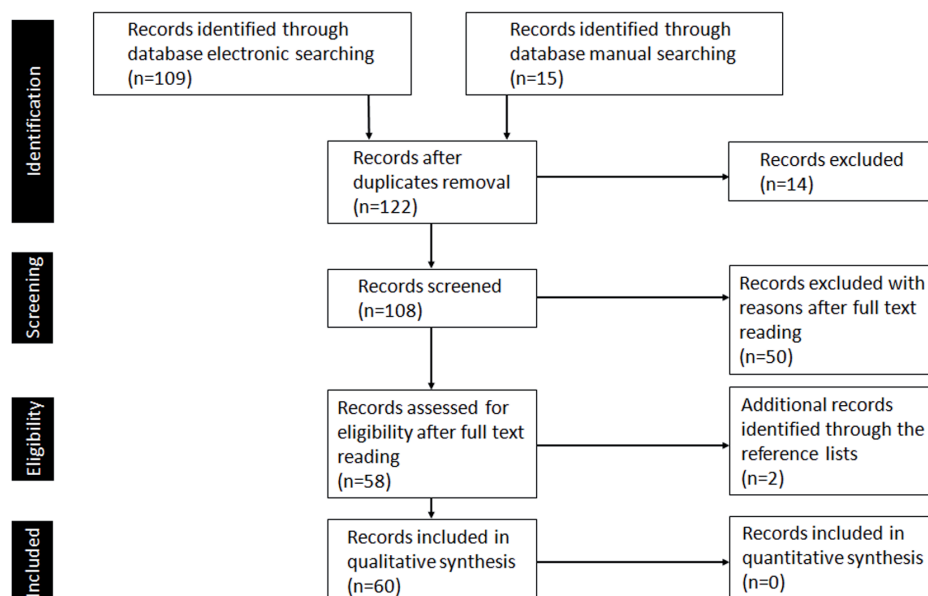
The number of dentists using intra-oral scanners in clinical practice is growing up. Today intraoral scans have a clinically acceptable precision level (13, 14). On the implants the scan is easier to do thanks to the use of dedicated components (scan-bodies) detectable by the scanner regardless how much deep is the implant platform respect to the gingival margin (15, 16, 17). In fixed prosthesis, a supragingival margin is preferable to maintain a sound periodontal attachment (18) but there are some clinical conditions in which the finish line needs to be placed subgingivally (19).

In these cases the opening of the gingival crevice is necessary to ensure accurate recording of the finish line by the scanner.

In a recent study Arcuri L et. all proposed a technique for improving subgingival scans through the use of radiosurgery (20). It is a controlled and accurate technique thanks to the use of the interim prosthesis as a guide for the tip of the radiosurgery electrode along the tooth surface to open selectively the gingival crevice with a prosthetically driven and minimally invasive approach. This approach allows the optical reading of the finish line of the subgingival preparations.

Although it is not the most common method, radiosurgery can also be used for traditional impressions. It can be used to trough around a tooth before the impression and before the cementation. This widens the sulcus into a funnel shape that allows the impression material to flow unimpeded. The electrode tip also removes tissue tags that could create notches along the finishing line in the impression. For anterior troughing, a thin wire electrode on the cut (filtered)

Tabella 1



waveform with the lowest possible power setting is critical in preventing tissue shrinkage and the possibility of having to remake the crown because of exposed margins (21).

Before this work, in 2013, Bellows purposes the use of radio surgical tip to create a sort of channel in the soft tissue around the prepared tooth to allow space for placement of impression material (11).

#### *Radiosurgery and dental surgery*

Radiosurgery has many applications in soft tissue management and in dental surgery. The radio wave produces a finer, less traumatic incision, and therefore has seen increased usage in all forms of delicate periodontal, implant, oral, and cosmetic surgery.

In implant surgery the specific current of 4 MHz makes it possible to undertake fine incisions in implant areas and offers maximum operative visibility, thanks to a non-hemorrhaging incision line. The thinness of the cutting line will subsequently make it possible to reposition the sides of the incision easily (22, 23). Radiofrequency facilitates the freeing of gingival tissue above the implant cover screw when it is brought into use. Radiofrequency microfibers allows to eliminate the mucosa covering without bleeding along with a sterilization of the incision surface. It is possible to shape the gingival area around the head of the implant to obtain the best possible aesthetic appearance of the prosthetic gingival contour (24).

The tip is placed in close proximity to the tissue before the power is activated. The tip is kept parallel to the implant to prevent removal of excessive tissue height. The incision is made in layers, waiting 10 seconds before re-entering the same surgical site (25).

Radiosurgery is excellent for managing the soft tissues when preparing for crowns and bridges. It can be used to contour the ridges upon which pontics will sit and to modify interproximal papillae. Surgical procedures that can be practiced with radiosurgery include development of an emergence profile for a pontic or an implant abutment, soft-tissue grafting elongation of a clinical crown, removal and contouring of hypertrophied tissues, maxillary frenulectomies, and various gingivoplasty procedures to establish a more suitable gingival architecture (21,26,27). The gingivectomy is the removal of suprabony soft tissue. This tissue can be fibrotic, thickened or hemorrhagic and soft. The gingivectomy is the removal of suprabony soft tissues. This tissues can be hemorrhagic and soft or fibrotic or thickened. Thickened fibrotic tissue as well as hemorrhagic tissue can be removed with the fully rectified waveform and a Vari-Tip (Ellman International) straight-wire electrode, to create a microsmooth incision and concurrent coagulation increasing the field of visibility. When this procedure is part of a preprosthetic surgery it is done to establish a more aesthetic smiling line before the positioning of crowns or veneers.

Then a gingivoplasty is performed to bevel the tissue using a round loop-shaped electrode. The tissue needs to heal for 2 to 3 weeks before prosthetic preparation to allow the tissue to heal (28).

Radiosurgery has given some results even in the removal of melanin hyperpigmentations of the gingiva. Hyperpigmentation is an aesthetic issue before a medical problem

(29) but can cause great discomfort to the patient's life. A slight and superficial application of radiosurgery is sufficient to remove pigmentation and patients report little or no discomfort during this procedure (30).

Some authors report the use of radiosurgical instruments for the elimination or reduction of the periodontal pocket. It provides reliable, rapid and precise contours for the repositioned or replaced gingival flap (31). In literature are reported cases of frenulectomy solved with radiosurgery. This procedure is effective and resolves serious cases of ankyloglossia in a predictable way (32).

Operculectomy is the removal of overgrown dense fibrous tissue that covers an impacted tooth to help eruption through removing the overlying gingiva. Radiosurgical unit can also be used to expose the impacted crowns (11). One of the true strengths of 4.0 MHz radiowave surgery is lesion removal. Incising fleshy or mobile tissue is always difficult. One problem with scalpel incision of fleshy or mobile tissue is that pressure is required, which distorts the tissue and decreases control and precision. The fine-tipped radiowave electrodes simply glide through the tissue without pressure. This pressureless incision technique is excellent for oral mucosa. A lot of different specialized electrodes are available for cosmetic uses. The Ellman Mucotome is an electrode that is specifically designed for harvesting palatal mucosa. These mucosa grafts are used for lower eyelid reconstruction and various maxillo- facial applications (33).

#### *Radiosurgery and Trigeminal Neuralgia*

Trigeminal neuralgia is a neuropathic condition involving cranial nerve V. It is characterized by the frequent occurrence of paroxysms of severe pain felt unilaterally in the distribution of the V cranial nerve alternating with periods of absence of pain and usually follows a chronic course with spontaneous remissions (34).

Medical treatment with anti-convulsant drugs such as carbamazepine, phenytoin or lamotrigine is usually considered as the first choice (35).

Radiofrequency thermocoagulation (RFT) is used to manage trigeminal neuralgia (TN) refractory to oral medication. It consists in giving heat to the gassing of Gasser through a small needle. The pathways of pain being weaker are the most damaged.

With this technique you can practice a focused treatment on the painful side.

It consists in applying heat to the gassing of Gasser through a small needle. The pathways of pain being weaker are the most damaged (36).

With this technique you can practice a focused treatment on the painful side. In a systematic review by Lopez et al. radiofrequency thermocoagulation is compared to others ablative techniques for treatment of trigeminal neuralgia such as glycerol rhizolysis, balloon microcompression, and stereotactic radiosurgery (37).

From seventy-seven studies they selected 4 studies including 1545 patients. RFT seemed to provide the highest rates of sustained complete pain relief, compared with other techniques. RFT is less invasive, has a lower morbidity, and the procedure can be repeated in the same patient if necessary. Complications associated to this technique include



postoperative trigeminal nerve sensory loss (38), keratitis (39), meningitis, transient cranial nerve deficits, and accidental vascular injuries resulting in hematomas or rarely carotid-cavernous fistulae (40).

#### *Radiosurgery and obstructive sleep apnea*

Obstructive sleep apnea syndrome (OSAS) is characterized by repetitive complete or partial upper airway collapse occurring during sleep. It affects 4 % of men and 2 % of women in the general population. It results in sleep fragmentation and oxygen desaturation (41). The airway obstructions are associated with fragmented sleep, gas exchange abnormalities and increased respiratory effort (42, 43).

Obstructive sleep apneas have a big health impact. They can cause: increased sympathetic activation, endothelial dysfunction, oxidative stress, enhanced state of inflammation, chronic intermittent hypoxia, (44, 45) sleep fragmentation leading to sleepiness, snoring and neuro-cognitive disturbance, hypertension, stroke, cardiovascular disease and insulin resistance (46-55).

Untreated OSAS is associated with motor vehicle accidents and occupational injuries (56-58).

The OSAS treatment requires the maintenance of an adequate airflow during sleep. The gold standard treatment for OSAS is continuous positive airway **pressure** (CPAP) (59, 60). Other kinds of treatment are oral **appliances** and, in case of oral abnormalities, curative surgery (61, 62).

Despite the great effectiveness of CPAP, patient's acceptance is very low so the adherence too is often low (63).

Oral appliances are designed to improve upper airway configuration and prevent collapse thanks to the alteration of jaw and tongue position. This appliance is called in different way: mandibular advancement splints (MAS), mandibular repositioning appliances (MRA), or mandibular advancement devices (MAD). In the most cases the mechanism of action is the same and it is to hold the lower jaw in a more anterior position (OAm) (64).

Some authors show that soft palate radio frequency ablation is a safe operative procedure that reduces snoring and sleepiness symptoms (65, 66). The intervention can be done in ambulatory, in local anesthesia. It involves the ablation of the soft palate by radiosurgery to increase the amount of air inhaled by the patient during sleep.

Various studies confirm that radiofrequency volumetric reduction of the palate can be considered as a successful therapy for Obstructive Sleep Apnea Syndrome represent a successful therapy (67-70).

In the most cases RW represents the second line treatment for mild to moderate OSA if CPAP therapy is not adhered to or tolerated (71). There are authors that indicate the radio-frequency ablation as a first-line treatment for moderate OSAS, with a low rate of complications (72).

#### *Radiosurgery and vital pulp therapy*

Vital pulp therapy is considered a good treatment option (73).

Dental pulp may be accidentally exposed during the preparation of deep cavities. Pulp direct capping is to apply a protective agent to an exposed pulp to preserve its function, health and vitality (74-76).

This procedure has been practiced for more than 200 years. Calcium hydroxide (CH) is widely accepted as the material of choice for direct pulp capping (77).

The response to direct pulp capping with materials such as calcium hydroxide (CH) is the formation of a dentin barrier, resulting from the recruitment and proliferation of undifferentiated cells (78, 79). Once differentiated, the cells synthesize a matrix that undergoes mineralization (80).

In direct pulp capping, clinical success also depends on the presence of an extrapulpal blood clot between the pulp and the capping material (81). It is necessary to control the hemostasis of the exposed pulp tissue.

Handa et al. did a study to assess the hemostasis and reparative dentin induction by high frequency radiowaves in the rat direct pulp capping model (82). They used 46 male rats divided into 5 groups; in the control group hemostasis was obtained by using 10% NaOCl and 3% H<sub>2</sub>O<sub>2</sub>. In the experimental groups, hemostasis was performed with radiowaves at various intensities (1, 4, 6, 8). In all the groups was used calcium hydroxide as direct capping agent. Hemostasis time was much lower in the experimental groups than in the control one probably thanks to the effects of HRW on transpiration and coagulation of soft tissue. Hemostasis with HRW prevents inflammatory reactions in dental pulp tissue and causes the formation of high-quality reparative dentin, when compared with other hemostasis procedures. The experimental groups showed a lower inflammatory level compared to the control group. Under a high magnification view, newly formed dentin shows a tunnel-like defect in control group.

Several studies have shown that mineral trioxide aggregate (MTA), compared with calcium hydroxide induces high quality reparative dentin (83, 84) so it represents the material of choice in direct pulp capping (85, 86). If hemostasis fails the result is unsatisfactory (87, 74). The hemostasis control done by radiowaves can increase the success of MTA in direct pulp capping.

## **Discussion**

Although in the scientific literature there are few articles on radiosurgery, its clinical applications are numerous. Radiosurgery is used in many fields of dentistry and we believe it is appropriate to study in deep its in clinical field. The benefits and better control of intraoperative complications and risks can lead clinicians to increasingly use radiosurgery in everyday clinical practice.

## **Bibliography**

1. Sherman JA. Implant exposure using radiosurgery. *Dent Today* 2007; 26:92-6
2. Lolis MS, Goldberg DJ. Radiofrequency in cosmetic dermatology: a review. *Dermatol Surg* 2012; 38:1765-76
3. Tepavcevic B, Matic P, Radak D. Comparison of sclerotherapy, laser, and radio wave coagulation in treatment of lower extremity telangiectasias. *J Cosmet Laser Ther* 2012; 14:239-42
4. Vinh NQ, Tani T, Naka S, et al. Thermal tissue change indu-

- ced by a microwave surgical instrument in a rat hepatectomy model. *Am J Surg* 2016; 211:189-96
5. Schoinohoriti OK, Chrysomali E, Tzerbos F, et al. Comparison of lateral thermal injury and healing of porcine skin incision performed by CO<sub>2</sub>-laser, monopolar electrosurgery and radiosurgery: a preliminary study based on histological and immunohistochemical results. *Int J Dermatol* 2012; 51:979-86
  6. Beasley KL, Weiss RA. Radiofrequency in cosmetic dermatology. *Dermatol Clin* 2014; 32:79-90
  7. Silverman E, Read R. Histologic comparison of canine skin biopsies collected using monopolar electrosurgery, CO<sub>2</sub> laser, radiowave radiosurgery, skin biopsy punch and scalpel. *Vet Surg* 2007; 56:36-50
  8. Sherman JA. *Oral Radiosurgery: An Illustrated Clinical Guide*. London: Martin Dunitz; 1997
  9. Maness WL, Rober FW, Clark RE, et al. Histological evaluation of electrosurgery incisions with varying frequency and waveform. *J Prosthetic Dent* 1978; 40:304-8
  10. Sharma S, Gambhir R, Singh S. Radiosurgery in dentistry-a brief review. *Annals of Dental Research* 2012; 2:8-20
  11. Bellows J. Laser and radiosurgery in veterinary dentistry. *Vet Clin North Am Small Anim Pract* 2013; 43:651-68
  12. Shuman IE. Bipolar versus monopolar electrosurgery: clinical applications. *Dent. Today* 2001; 20:74-81
  13. Ahlholm P, Sipilä K, Vallittu P, et al. Digital Versus Conventional Impressions in Fixed Prosthodontics: A Review. *J Prosthodont* 2018; 27:35-41
  14. Arcuri L, De Vico G, Ottria L, et al. Smart fusion vs. double scan: a comparison between two data-matching protocols for a computer guided implant planning. *Clin Ter* 2016; 167(3):55-62
  15. Brandt J, Lauer H-C, Peter T, et al. Digital process for an implant-supported fixed dental prosthesis: A clinical report. *J Prosthet Dent* 2015; 114:469-73
  16. Arcuri L, Lorenzi C, Cecchetti F, et al. Full digital workflow for implant-prosthetic rehabilitations: a case report. *Oral Implantol* 2015; 8:114-21
  17. Corridore D, Guerra F, La Marra C, et al. Oral Health Status and Oral Health-Related Quality of Life in Italian Deinstitutionalized Psychiatric Patients. *Clin Ter* 2017; 168(2):e77-83
  18. Podhorsky A, Rehmann P, Wöstmann B. Tooth preparation for full-coverage restorations-a literature review. *Clin Oral Invest* 2015; 19:959-68
  19. Padbury A, Eber R, Wang H-L. Interactions between the gingiva and the margin of restorations. *J Clin Periodontol* 2003; 30:379-85
  20. Arcuri L, Contaldo M, Santoro R. Radiosurgery-assisted gingival displacement: a proof of concept technique to enhance the efficiency of intraoral digital impression. *J Biol Regul Homeost Agents*. 2018; 32:197-201
  21. Rossein K. Predictable soft tissue management with radiosurgery. *Dent Today* 2003; 22:80-3
  22. Ferris RT. Periodontal-flap management is improved with radiosurgery. *Dent Econ* 1993; 83:96-7
  23. Arcuri C, Cecchetti F, Germano F, et al. Clinical and histological study of a xenogenic bone substitute used as a filler in postextractive alveolus. *Minerva stomatologica* 2005; 54:351-62
  24. Guillaume B. Implant surgery and high-frequency currents. Operative indications. *Dent Today* 2003; 22:80-85
  25. Sherman JA. Implant exposure using radiosurgery. *Dent Today*. 2007; 26:92-6
  26. Escalante Vasquez R. The minimally invasive closed osteotomy. *Dent Today* 2011; 30:160-3
  27. Smith MM. Gingivectomy, gingivoplasty, and osteoplasty for mandibular canine tooth malocclusion. *J Vet Dent* 2013; 30:184-97
  28. Sherman JA. Cosmetic gingivectomy using radiosurgery. *Dent Today*. 2014; 33:124-6
  29. Page LR, Corio LR, Crawford BE, et al. The oral melanotic macule. *Oral Surg Oral Med Oral Pathol* 1977; 44:219-26
  30. Sherman JA, Gurkan A, Arikian F. Radiosurgery for gingival melanin depigmentation. *Dent Today* 2009; 28:118-21
  31. Ferris RT. Periodontal-flap management is improved with radiosurgery. *Dent Econ* 1993; 83:96-7
  32. Sherman JA. Oral surgery simplified with radiosurgery. *Dent Today*. 2008; 27:123-6
  33. Bell W, Guerrero C. *Distraction Osteogenesis of the Facial Skeleton*. Elsevier, 2007
  34. Lettmaier S. Radiosurgery in trigeminal neuralgia. *Phys Med* 2014; 30:592-5
  35. Sindrup SH, Jensen TS. Pharmacotherapy of trigeminal neuralgia. *Clin J Pain* 2002; 18:22e27
  36. Jin HS, Shin JY, Kim YC, et al. Predictive Factors Associated with Success and Failure for Radiofrequency Thermocoagulation in Patients with Trigeminal Neuralgia. *Pain Physician* 2015; 18:537-45
  37. Lopez BC, Hamlyn PJ, Zakrzewska JM. Systematic review of ablative neurosurgical techniques for the treatment of trigeminal neuralgia. *Neurosurgery* 2001; 54:973-82
  38. Zakrzewska JM, Jassim S, Bulman JS. A prospective, longitudinal study on patients with trigeminal neuralgia who underwent radiofrequency thermocoagulation of the gasserian ganglion. *Pain* 79: 51-8
  39. Pollock BE, Phuong LK, Foote RL, et al. High-dose trigeminal neuralgia radiosurgery associated with increased risk of trigeminal nerve dysfunction. *Neurosurgery* 2001; 49:58-64
  40. Kanpolat Y, Savas A, Bekar A, et al. Percutaneous controlled radiofrequency trigeminal rhizotomy for the treatment of idiopathic trigeminal neuralgia: 25-year experience with 1,600 patients. *Neurosurgery* 2001; 48:524-34
  41. Young T, Palta M, Dempsey J, et al. (1993) The occurrence of sleep-disordered breathing among middle-aged adults. *N Engl J Med* 1993; 328:1230-5
  42. American Academy of Sleep Medicine. *The AASM manual for the scoring of sleep and associated events: rules, terminology and technical specifications*. 1st ed. Westchester: Illinois; 2007
  43. Katz ES, D'Ambrosio CM. Pediatric obstructive sleep apnea syndrome. *Clin Chest Med* 2010; 31:221-34
  44. Kohler M, Stradling JR. Mechanisms of vascular damage in obstructive sleep apnea. *Nat Rev Cardiol* 2010; 7:677-85
  45. Ryan S, Taylor CT, McNicholas WT. Systemic inflammation: a key factor in the pathogenesis of cardiovascular complications in obstructive sleep apnoea syndrome? *Postgrad Med J* 2009 85:693-8
  46. Al-Lawati NM, Patel SR, Ayas NT. Epidemiology, risk factors, and consequences of obstructive sleep apnoea and short sleep duration. *Prog Cardiovasc Dis* 2009; 51:285-93
  47. Butkov N, Lee-Chiong T. *Fundamentals of sleep technology*. Philadelphia. Lippincott Williams & Wilkins, 2007
  48. Young T, Palta N, Dempsey J. The occurrence of sleep disordered breathing among middle-aged adults. *N Eng J Med* 1993; 32:1230-5
  49. Tsai JC. Neurological and neurobehavioural sequelae of obstructive sleep apnea. *Neurorehabilitation* 2010; 26:85-94

50. Peker Y, Hedner J, Norum, et al. Increased incidence of cardiovascular disease in middle-aged men with obstructive sleep apnea: A 7-year follow-up. *American Journal of Respiratory and Critical Care Medicine* 2002; 166:159–65
51. Pepperell JC. Sleep apnoea syndromes and the cardiovascular system. *Clinical Medicine* 2011;11:275–8
52. Carlson JT, Hedner JA, Ejnell H, et al. High prevalence of hypertension in sleep apnea patients independent of obesity. *American Journal of Respiratory and Critical Care Medicine* 1994;150:72–7
53. Drager LF, Genta PR, Pedrosa RP, et al. Characteristics and predictors of obstructive sleep apnea in patients with systemic hypertension. *American Journal of Cardiology* 2010; 105:1135–9
54. Ip MS, Lam B, Ng MM, et al. Obstructive sleep apnea is independently associated with insulin resistance. *American Journal of Respiratory and Critical Care Medicine* 2002;165: 670–6
55. Babu AR, Herdegen J, Fogelfeld L, et al. Type 2 diabetes, glycemic control, and continuous positive airway pressure in obstructive sleep apnea. *Archives of Internal Medicine* 2005; 165:447–52
56. Al-Ghanim N, Comondore VR, Fleetham J, et al. The economic impact of obstructive sleep apnoea. *Lung* 2008; 186:7-12
57. Hillman DR, Murphy AS, Pezzullo L. The economic cost of sleep disorders. *Sleep* 2006; 29:299-305
58. Sassani A, Findley LJ, Kryger MD, et al. Reducing motor-vehicle collisions, costs, and fatalities by treating obstructive sleep apnoea. *Sleep* 2004; 27:453-8
59. Kryger MH. *Atlas of clinical sleep medicine*. Philadelphia. Saunders Elsevier, 2010
60. Weaver TE, Grunstein RR. Adherence to continuous positive airway pressure therapy. *Proc Am Thorac Soc* 2008; 5:173-178
61. Kushida CA, Littner MR, Hirshkowitz M, et al. American Academy of Sleep Medicine Practice parameters for the use of continuous and bilevel positive airway pressure devices to treat adult patients with sleep-related breathing disorders. *Sleep* 2006; 29:375–80
62. Kushida CA, Morgenthaler TI, Littner MR, et al. American Academy of Sleep Practice parameters for the treatment of snoring and obstructive sleep apnea with oral appliances. *Sleep* 2006; 29:240–3
63. Kribbs NB, Pack AI, Kline LR, et al. Objective measurement of patterns of nasal CPAP use by patients with obstructive sleep apnea. *Am Rev Respir Dis* 1993; 147:887-95
64. Chan ASL, Sutherland K, Schwab RJ, et al. The effect of mandibular advancement on upper airway structure in obstructive sleep apnoea. *Thorax* 2010; 65:726-32
65. Bäck LJ, Hytönen ML, Roine RP, et al. Radiofrequency Ablation Treatment of Soft Palate for Patients with Snoring: A Systematic Review of Effectiveness and Adverse Effects. *Laryngoscope* 2009; 119:1241-50
66. Powell NB, Riley RW, Troell RJ, et al. Radiofrequency volumetric tissue reduction of the palate in subjects with sleep-disordered breathing. *Chest* 1998; 113:1163-74
67. Riley RW, Powell NB, Li KK, et al. An adjunctive method of radiofrequency volumetric tissue reduction of the tongue for OSAS. *Otolaryngology—Head and Neck Surgery* 2003; 129:137–42
68. Stuck BA, Maurer JT, Verse T, et al. Tongue base reduction with temperature-controlled radiofrequency volumetric tissue reduction for treatment of obstructive sleep apnea syndrome. *Acta Oto-Laryngologica* 2002;122:531-6
69. Steward DL, Weaver EM, Woodson BT. Multilevel temperature-controlled radiofrequency for obstructive sleep apnea: extended follow-up. *Otolaryngology—Head and Neck Surgery* 2005; 132:630–5
70. Li KK, Powell NB, Riley RW, et al. Radiofrequency volumetric reduction of the palate: an extended follow-up study. *Otolaryngology—Head and Neck Surgery* 2000; 122:410–14
71. Aurora RN, Casey KR, Kristo D et al. Practice parameters for the surgical modifications of the upper airway for obstructive sleep apnea in adults. *Sleep* 2010; 33:1408–13
72. Sonsuwan N, Rujimethabhas K, Sawanyawisuth K. Factors Associated with Successful Treatment by Radiofrequency Treatment of the Soft Palate in Obstructive Sleep Apnea as the First-Line Treatment. *Sleep Disord.* 2015; 2015:690425
73. Aguilar P, Linsuwanont P. Vital pulp therapy in vital permanent teeth with cariously exposed pulp: a systematic review. *J Endod* 2011; 37:581–7
74. Silva GA, Gava E, Lanza LD, et al. Subclinical failures of direct pulp capping of human teeth by using a dentin bonding system. *J Endod.* 2013; 39:182-9
75. Camp JH, Fuks AB. Pediatrics: endodontic treatment for the primary and young permanent dentition. In: Cohen S, Hargreaves KM, eds. *Pathways of the pulp* (ed.IX). MO: Mosby Elsevier, St Louis, 2006; 822–82
76. Fuks AB. Vital pulp therapy with new materials for primary teeth: new directions and treatment perspectives. *J Endod* 2008; 34:18–24
77. Mente J, Hufnagel S, Leo M, et al. Treatment outcome of mineral trioxide aggregate or calcium hydroxide direct pulp capping: long-term results. *J Endod.* 2014; 40:1746-51
78. Goldberg M, Smith AJ. Cells and extracellular matrices of dentin and pulp: a biological basis for repair and tissue engineering. *Crit Rev Oral Biol Med* 2004; 15:13-27
79. Schroder U. Effects of calcium hydroxide-containing pulp-capping agents on pulp cell migration, proliferation, and differentiation. *J Dent Res* 1985; 64:541-8
80. Schroder U. Effect of an extra-pulpal blood clot on healing following experimental pulpotomy and capping with calcium hydroxide. *Odontol Revy* 1973; 24:257–68
81. Handa K, Koike T, Hayashi K, et al. Application of high-frequency radio waves to direct pulp capping. *J Endod* 2013; 39:1147–50
82. Hirschman WR, Wheeler MA, Bringas JS, et al. Cytotoxicity comparison of three current direct pulp-capping agents with a new bioceramic root repair putty. *J Endod* 2012; 38:385–8
83. Nair PN, Duncan HF, Pitt Ford TR, et al. Histological, ultrastructural and quantitative investigations on the response of healthy human pulps to experimental capping with mineral trioxide aggregate: a randomized controlled trial. *Int Endod J* 2009; 42:422–44
84. Cho SY, Seo DG, Lee SJ, et al. Prognostic factors for clinical outcomes according to time after direct pulp capping. *J Endod* 2013; 39:327–31
85. Hilton TJ, Ferracane JL, Mancl L. Comparison of CaOH with MTA for direct pulp capping: a PBRN randomized clinical trial. *J Dent Res* 2013; 92:16S–22
86. Sannino G, Germano F, Arcuri L, et al. CEREC CAD/CAM chairside system. *Oral and Implantology* 2014; 7:57-70
87. Jayawardena JA, Kato J, Moriya K, et al. Pulpal response to exposure with Er:YAG laser. *Oral Surg Oral Med Oral Pathol Oral Radiol Endod* 2001;91:222–9