

Nanofat Grafting for Scar Treatment and Skin Quality Improvement

Semra Uyulmaz, MD; Nadia Sanchez Macedo, PhD; Farid Rezaeian, MD; Pietro Giovanoli, MD; and Nicole Lindenblatt, MD

Aesthetic Surgery Journal
2018, Vol 38(4) 421–428
© 2018 The American Society for
Aesthetic Plastic Surgery, Inc.
Reprints and permission:
journals.permissions@oup.com
DOI: 10.1093/asj/sjx183
www.aestheticsurgeryjournal.com

OXFORD
UNIVERSITY PRESS

Abstract

Background: Fat grafting has been gaining attention in tissue augmentation over the past decade, not only for lipofilling, but also for its observed regenerative properties and overall skin texture improvement.

Objectives: The aim of this study was to analyze the effect of nanofat grafting on scars, wrinkles, and skin discolorations in our clinic.

Methods: Nanofat was prepared by a standard emulsification and filtration protocol. The resulting liquid was injected intradermally or directly into the scar tissue. Skin quality was evaluated based on a scoring system, and patient satisfaction was documented. Three physicians compared and analyzed standardized pre- and posttreatment photographs in respect to general improvement of skin aesthetics.

Results: Fifty-two patients were treated with nanofat from November 2013 to April 2016. The mean (\pm standard deviation) posttreatment follow up was 155 ± 49 days and average volume of harvested fat amounted to 165 cc. The primary harvesting areas were the abdomen and flanks, and the injected volume of nanofat ranged from 1 to 25 mL (mean, 4.6 mL). A total of 40 scars (76% of all patient defects) were effectively treated as well as 6 patients with wrinkles, and 6 patients with discoloration. Posttreatment clinical evaluations showed a marked improvement of scar quality and a high patient satisfaction. The results in our clinic showed that nanofat grafting softened the scars, made discolorations less pronounced, and wrinkles appeared less prominent.

Conclusions: Nanofat grafting has been shown to have beneficial effects in the treatment of scars, wrinkles, and skin discolorations.

Level of Evidence: 4



Editorial Decision date: September 8, 2017; online publish-ahead-of-print January 20, 2018.

Several skin conditions such as scars or signs of aging, including wrinkles and discolorations may negatively affect skin appearance and aesthetic. Scarring is a natural process that occurs after wound healing. However, the appearance and visibility of scars depends on multiple factors. Injection, or topical application of corticosteroids onto pathologic scars are considered an effective treatment method for keloids and hypertrophic scars.¹ Nonetheless, irreversible subcutaneous atrophy and hypopigmentation are limiting side effects.² Hypopigmentation can also occur in cryotherapy, and radiotherapy scar treatment may involve multiple sessions and can entail unwanted cellular apoptosis and necrosis.³ Scars are also often treated with less invasive silicone dressings and pressure garments, but

their positive effects currently lack scientific evidence.³ Laser therapy of hypertrophic scars may improve their appearance yet nevertheless, laser technology is limited by high recurrence rates and skin discoloration.⁴ Finally, surgery may be an option to correct overly conspicuous scars and includes skin grafting, excision, and direct closure or

From the Division of Plastic and Hand Surgery, Department of Surgery, University Hospital Zurich, Zürich, Switzerland.

Corresponding Author:

Prof. Dr Nicole Lindenblatt, Division of Plastic and Hand Surgery, Department of Surgery, University Hospital Zurich, Raemistrasse 100, 8091 Zurich, Switzerland.
E-mail: nicole.lindenblatt@usz.ch

dermabrasion. However, invasive surgical procedures may be associated with higher rates of complications resulting in even larger scars with persistent retraction, which may worsen the situation.⁵ With that, current scar therapies generally make use of ablative mechanisms, which may involve irreversible side effects, therefore emphasizing the need for alternative methods.

Autologous fat grafting has become quite popular in tissue reconstruction and augmentation over the past decade. Its regenerative properties and beneficial effects with respect to skin texture have been observed in several studies.^{6,7} Hyperpigmentation, skin texture, and scar quality may equally play an important role in determining a suitable treatment and resulting outcome. Consequently, Tonnard et al⁸ described a new technique introducing nanofat and hypothesized that it could be applied in various other skin conditions such as wrinkles and discolorations. Wrinkles and skin discolorations are usually addressed with expensive dermatological treatments such as “fillers” and erosive chemical peelings that require numerous sessions. Such treatments often have no permanent effect. Therefore, wrinkles and discolorations might also benefit from the long-term regenerative properties of nanofat.

The aim of this study was therefore to analyze the effect of nanofat on skin quality improvement in scars, wrinkles, and discoloration, and to report on its safety, feasibility, and posttreatment patient satisfaction.

METHODS

We performed a single center retrospective analysis study to evaluate the effect of nanofat grafting in patients who were treated for scars, wrinkles, or discolorations from November 2013 to April 2016 in our clinic. This study was approved by the Cantonal Ethic Committee of Zurich, and all patient photographs shown have given written consent.

After infiltration with a standardized fat harvesting solution (900 mL NaCl 0.9%, 0.25 mL Adrenalin (1 mg/mL), 20 mL of Lidocain (20 mg/mL), microfat was harvested using the Tonnard Harvester 2.4 mm × 20 cm cannula with sharp side holes of 1 mm in diameter (Tulip Medical Products, San Diego, CA). Donor sites were chosen according to fat deposits and preferences of the patient. Harvested fat was washed with isotonic saline solution. Nanofat was prepared in a standardized manner: microfat was mechanically emulsified by shifting the contents 30 times back and forth between two 10 cc syringes connected to each other by the 2.4 mm Tulip transfer until the fat became liquefied and acquired a whitish appearance. Then the emulsified fat was pressed through a nylon cloth with 0.5 mm pore size to filtrate it and was then transferred into sterile 1 mL syringes for injection.

The obtained liquid was injected with 24, 25, or 27-gauge sharp needles into the scar tissue or the dermis

respectively. Needle diameter was dependent upon the quality and rigidity of the scar tissue. With that, we also assumed that if nanofat promotes tissue regeneration and improves skin quality in scars, it could also reduce the appearance of superficial skin wrinkles, such as those seen around the eyes or mouth. These very fine superficial lines cannot effectively be addressed by direct volume replacement and nanofat is generally employed to improve overall skin quality. With that, nanofat was also applied with many small intradermal injections over the entire affected area as a resurfacing treatment. Single rhytides were not addressed or injected. The endpoint of injection was reached with the appearance of yellowish discoloration of the skin during the injection process. Patients were seen in our outpatient clinic after seven days, three weeks, and three months post treatment. Skin and scar quality was documented during each visit. A patient satisfaction assessment was performed on their last follow-up consultation by an interview in person with the consulting physician. Each patient was asked if he or she was satisfied with the result or not. Patients answered with either a yes or no and no specific scales or written surveys were utilized. Patients' remarks were documented in their medical record and the data was collected retrospectively. Standard pre- and posttreatment photographs were evaluated by three physicians in order to determine the improvement of skin appearance: a dermatologist, a plastic surgeon, and a general surgeon. These three physicians completed their evaluations separately and independently. In order to evaluate the results a visual three-grade scale was used, which is described below:

Score 1: good result;

Score 2: satisfactory result;

Score 3: no change.

Reviewers were additionally allowed to make remarks if a posttreatment result seemed worse than before.

The indication for nanofat was provided when a patient wanted to visibly reduce wrinkles or discoloration in their face permanently, or if scars in the face and body were either very conspicuous due to widening and hyperpigmentation, or functional retraction. We excluded all patients with contraindications, such as previously reported hypersensitivity to the specific procedure, severe skin disease, and acute infection. We performed all procedures under general anesthesia for the patient's convenience based on their preference. However, it is also possible to apply nanofat under local anesthesia.

RESULTS

All 52 consecutive patients included in this study were followed up on in our outpatient clinic after treatment. Forty patients were female (77%) and 12 patients were male (23%). The age of the patients ranged from 15 to 64 years (mean, 42 years). The average age of scars ranged from 15 months

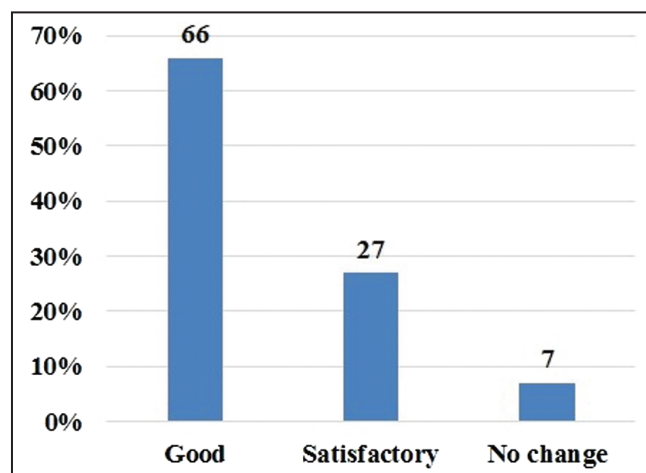


Figure 1. Evaluation of the reviewers' estimation of the surgical results (percentage).

to 40 years (mean, 5.8 years). A total of 40 scars (76%) were treated. Six patients with wrinkles and six patients with discoloration were treated for skin quality improvement. Two patients received laser therapy, one radiotherapy, and one dermabrasion before treatment. All of these patients suffered from scars. One additional patient with discolorations was previously treated with dermabrasion.

Main treatment areas were scars of the face and body, and discoloration or wrinkles in the face, neck, and décolleté. The average volume of harvested fat was 165 cc (range, 10-800 mL). Main harvesting areas were the abdomen and flanks. Nanofat injections were generally performed once. In four cases, nanofat treatment was performed twice as three of these four patients had rigid scars, which were nonetheless significantly softened after the first treatment. In the follow-up period, both the examiner and patient decided to perform a second treatment in order to soften the remaining rigid tissue as well. One of the above-mentioned patients suffered from discolorations after laser treatment for scars. A second treatment with nanofat was undertaken and significantly improved skin color was noted posttreatment. The second treatment was performed respectively after three months.

The injected volume of nanofat ranged from 1 to 25 mL (mean, 4.6 mL). The mean (\pm standard deviation) posttreatment follow up was 155 ± 49 days (range, 87-312 days). There were no significant complications. Additionally, no fat cysts, infections, foreign body reactions, permanent discolorations, or other side effects were observed directly after the treatment and in the follow-up period. Some patients reported minor temporary pain at the harvesting site. Results of all 52 cases were clinically evaluated in our outpatient clinic. In general, scars were described as softer or less prominent, wrinkles as less deep, and discoloration as less noticeable as per the consulting physician. Eight patients were followed up in the outpatient clinic

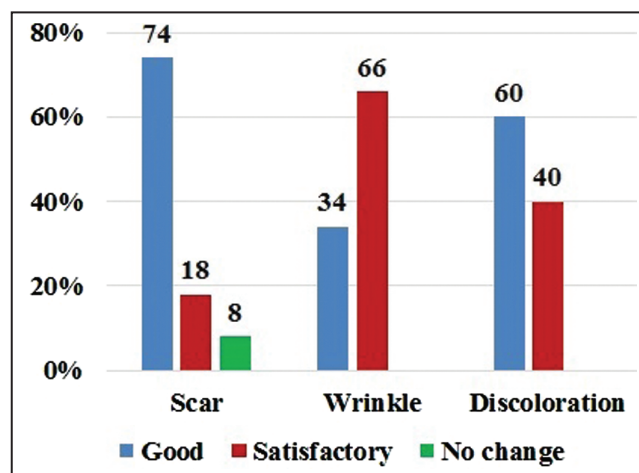


Figure 2. Reviewers rating regarding results for specific lesion (percentage). Scars and discoloration seem to benefit most from nanofat treatment.

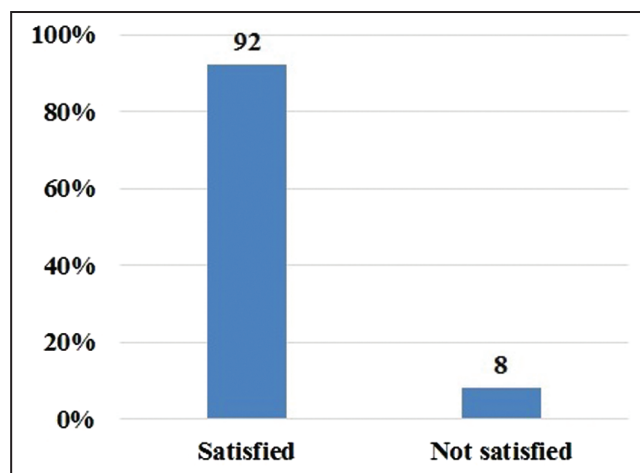


Figure 3. Patient satisfaction (percentage).

without documented posttreatment pictures. In seven of these cases, examiners had described scars to be softer and less visible. In one case, a hyperpigmented lower eyelid area was described as less pronounced by the examiner. An improvement of skin quality or appearance was however noticeable at 100 days posttreatment.

A total of 44 pre- and posttreatment photographs were evaluated by three types of doctors. Overall, evaluations presented a substantial improvement of skin appearance in 93% of all cases, with general consensus from all reviewers (Figure 1).

Reviewers classified the results in the majority of scars posttreatment as good (74%) (Figure 2). The results in 18% of the treated scars were rated as satisfactory and only 8% of all treated scars were rated as unchanged posttreatment. Posttreatment results in discolorations were rated as good (60%), and as satisfactory (40%) by the

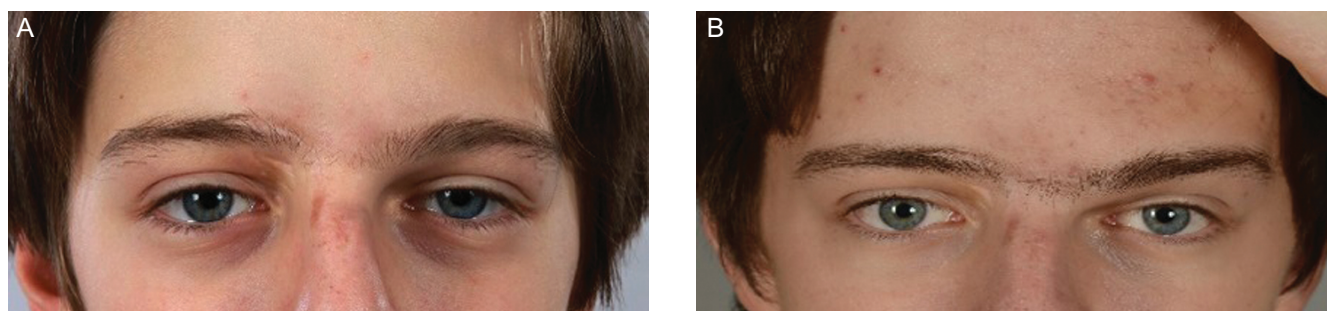


Figure 4. (A) A 17-year-old male patient with a hyperpigmented scar at the root of the nose after a nasal fistula 2 years before and periorbital discolorations. (B) Three month posttreatment the scar is smaller and less conspicuous and skin discolorations are evened out. Two mL nanofat was injected intradermally. The patient shows visible hair growth in the glabella area in the pretreatment picture, so most likely the hair was plucked or shaved.

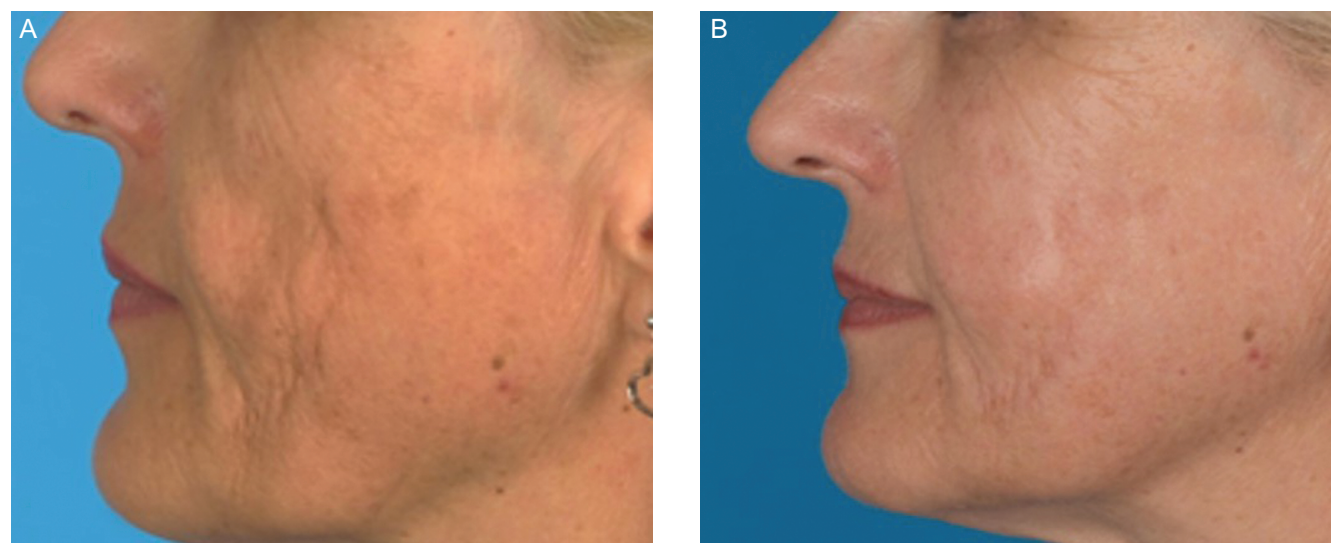

Figure 5. (A) A 52-year-old female patient with a hyperpigmented irregular skin lesion of the left cheek after a dog bite injury 40 years ago. (B) Four month posttreatment: the scar is less visible and irregularities have disappeared. A total of 1.6 mL nanofat was applied intradermally.

reviewers. Posttreatment results of wrinkles were rated as satisfactory in the majority of the cases (66%). In 34% of treated wrinkles, results were rated as good posttreatment. None of the reviewers rated a posttreatment result in scars, wrinkles or discolorations as worse than before.

Forty eight of our 52 patients (92%) were highly satisfied with their results as noted in the patients' history by the clinical examiner (Figure 3). Pre- and posttreatment pictures of 6 patients are included to demonstrate the effect of nanofat on scars and skin appearance (Figures 4–7 and Supplemental Figures 1 and 2, available as Supplementary Material at www.aestheticsurgeryjournal.com).

DISCUSSION

Currently, the classical scar correctional procedure has been surgical excision, which often results in the enlargement of the scar length and remaining or reoccurring hypertrophy

or redness. Fat grafting has been shown to have beneficial effects on contracted scars, which were initially treated for volume loss. The first autologous fat transfer for volume loss in the face was described in 1893, when fat was used *en bloc* for filling up subcutaneous defects.⁹ In 1912 a retracted scar after mastectomy was corrected with fat injections.¹⁰ In recent times, however, the technique of fat harvesting and injection has been refined and significantly improved, therefore also yielding more desirable results.

Since adipose tissue is biocompatible and not immunogenic it represents an ideal transplant material for a patient. Furthermore, it is easy to harvest and is associated with low donor site morbidity. In previous clinical observations, adipose tissue was shown to have regenerative effects in the dermis and subcutaneous tissue.^{11–13} However, the underlying mechanisms involved in improving tissue quality remain unclear. Studies imply that the formation of new blood vessels, tissue remodeling, and inflammatory responses as potential reasons for scars that are able to

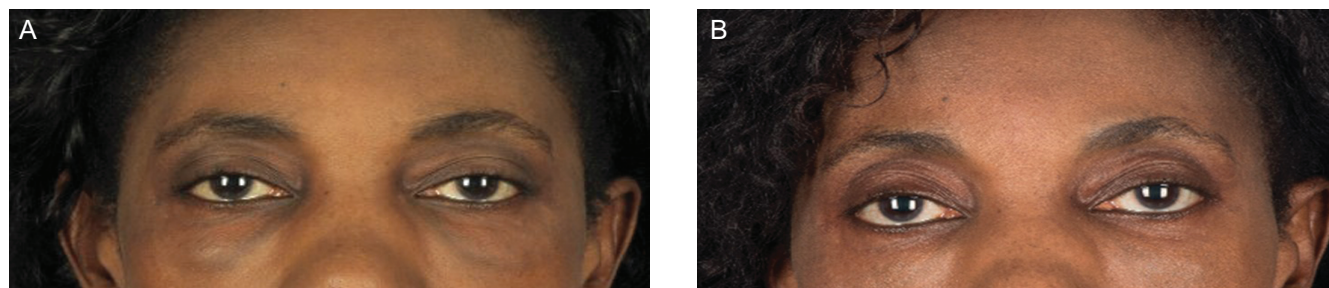


Figure 6. (A) A 49-year-old female patient with periorbital hyperpigmentation. (B) One month posttreatment, dark circles around her eyes have almost disappeared. 1 mL nanofat was injected intradermally per side.

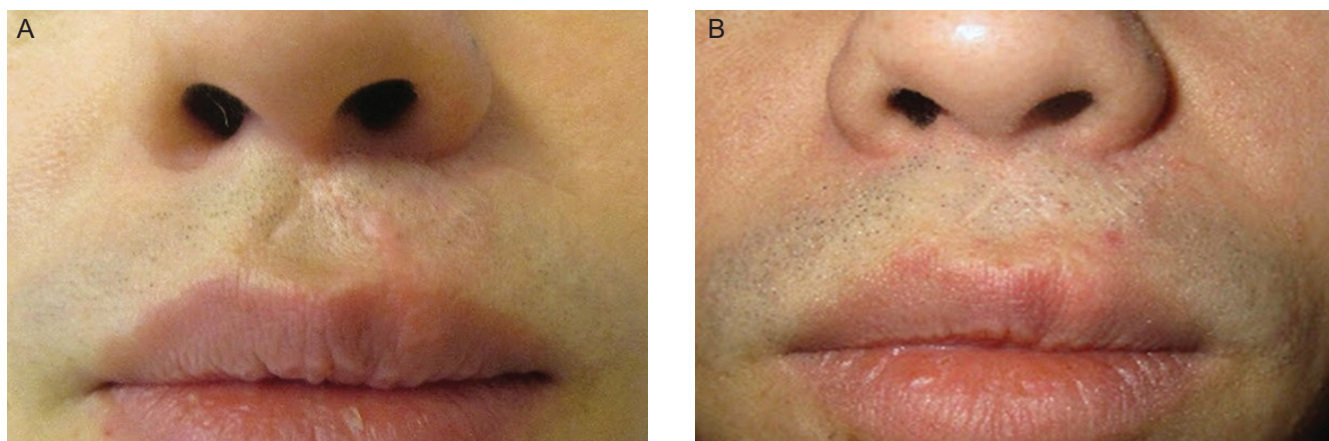


Figure 7. (A) A 35-year-old male patient with a scar from a contused laceration of the upper lip 1.5 years after an accident. (B) Six month posttreatment there was no elevation notable and the scar was softer. A total of 2.5 mL nanofat was applied intradermally.

regain characteristics of normal skin. There is mutual consent that adipose tissue derived stem cells (ADSCs) are multi- and pluripotent.¹⁴⁻¹⁶ ADSCs can be found in great amounts in the stromal vascular fraction (SVF) of adipose tissue.¹⁷ In an experimental study, Zhang et al injected adipose tissue derived stem cells intralesionally into rabbit ears and showed that the formation of hypertrophic scarring was reduced thereafter by decreasing the α -SMA and collagen type I gene expression and enhancing collagen deposition.¹⁸ In a murine model fat grafting was performed to irradiated skin and photometrical and histological examinations were conducted posttreatment.¹⁹ It was shown that fat grafting restores collagen organization and downregulates the fibrotic response to radiation. Fat grafting most likely promotes improvement through mesenchymal cells and numerous growth factors already contained in the lipoaspirate, which contributes to skin and scar remodeling. In several studies, elasticity and plasticity of the scar tissue was increased, which was also revealed microscopically in posttreatment scar samples.^{20,21}

The term “nanofat” was introduced by Tonnard et al in 2013 describing a new method to prepare autologous fat in order to predominantly make use of its regenerative

properties. They investigated the viability of adipocytes and the number and activity of the adipose derived stem cells (ADSCs) in comparison to lipoaspirates obtained by standard fat harvesting techniques. They demonstrated that no viable adipocytes were left after the emulsification process, but the number of ADSCs was comparable to standard lipoaspirates. However, fat tissue is composed of adipocytes and a number of other cells referred to as SVF.¹¹ Adipocytes only comprise of 25% of the total cell count in fat tissue. Based on this, since the SVF and the ADSCs are not removed from the solution before injection, the prepared tissue can still be termed as a form of fat. The main clinical application of nanofat is not filling up soft tissue defects, but rather to stimulate tissue regeneration and remodeling.⁸ Adipose tissue is shuffled intersyringeal to create nanofat. Shuffling the lipoaspirate up to 30 times simplifies its injection. The intensity and approach to the shuffling procedure might have an impact on the yielded nanofat. Osinga et al however demonstrated that the mechanical procedure of shuffling lipoaspirated fat does not alter the tissue viability or its microscopic structure, and that there is no impact on the SVF.²² Based on their in vitro findings, they suggested that shuffling may be

applied in order to make fat injections easier without damaging the fat cells.²² However, the correct nanofat preparation includes an additional step (ie, the filtering of the fat obtained after shuffling through a mesh with a 0.4-0.6 mm pore size), which inevitably destroys the adipocytes. Therefore, correctly prepared nanofat is not suitable for volume replacement, as it merely consists of purely regenerative properties.

It was demonstrated that nanofat contains no viable adipocytes, however, an amount of ADSCs that is comparable to microfat. In an attempt to characterize the potential regenerative benefits, it was experimentally shown that nanofat processing via mechanical lipoaspirate emulsification does not only disrupt adipose cells to create an injectable liquid.²³ The viscosity of nanofat was analyzed and SVF was isolated and quantified. Mechanical processing was shown to lead to a shear-stress-induced upregulation of certain progenitor cell phenotypes that are associated with multipotency and pluripotency. Specifically, adipose-derived-stem cells and endothelial progenitor cell phenotypes were detected in larger amounts in the mechanically processed lipoaspirate, which might be the reason why nanofat grafting seems to have potent regenerative effects with clinically remarkable results.

Additionally, Rohrich et al studied the differences in adipocyte viability depending on the donor area and concluded that there were no significant differences in adipocyte viability among the abdomen, thighs, or flanks.²⁴ Differences in the quantity of stem cells depending on donor area are however still postulated in literature.²⁵ We did not detect any significant difference in results depending on donor sites in our clinical application.

Microneedling is also known as percutaneous collagen induction, which appears to be an overall effective and safe therapeutic option for numerous dermatologic conditions.²⁶ The target of the needles is the upper dermis. Microwounds created in this case stimulate the release of growth factors and induce collagen production.^{27,28} The epidermis remains intact, therefore reducing adverse events. The efficacy of microneedling for the treatment of scars and skin rejuvenation was demonstrated clinically in several studies.^{29,30} Nanofat too, is injected with sharp needles intradermally. Therefore, a needling effect cannot completely be ruled out in nanofat grafting, and may actually contribute to the overall beneficial effect of nanofat. However, the number of microwounds caused by the injection are minimal in effort to prevent an unnecessary outflow of the fluid.

Tonnard et al⁸ published remarkable clinical results of skin quality improvement after nanofat treatment in 67 patients that are consistent with the aesthetically satisfactory results that were obtained in our own patient series. Skin has been observed as softer and more flexible, and discolorations blended into the surrounding healthy

skin. The advantage of nanofat for scar treatment is that it introduces regenerative properties and does not create new scars. Furthermore, the risk of abnormal healing is low as no new surgical intervention is applied to the skin. Additionally, no special posttreatment treatment is required. A single session seems to be sufficient, although in some cases more sessions can be beneficial. Another advantage is that it can be easily combined with traditional fat grafting. In this way, skin quality improvement can for example prevent or improve cases where severe retractile scarring is prevalent, for example in breast implantation. It can also make cicatrice tissues suitable to accept prosthesis and expanders. It also seems that reddened and slightly elevated scars (Figures 4 and 7, and Supplemental Figures 1 and 2) and discolorations (Figure 6) benefit the most from nanofat. We however suggest that as nanofat causes tissue regeneration and improves skin quality it can also increase dermal elasticity, and therefore the elasticity of deep wrinkles. In this study an improvement of skin quality or appearance was noticeable up to 100 days post-treatment on average. However, from our clinical experience, after the evaluation period we often noticed that the effects are long-lasting and may even further improve after 3 months. Further long-term studies are needed in order to clearly document the longevity of this action in greater detail.

The average age of the treated scars in this study ranged from 15 months to 40 years and the majority of them were traumatic. Therefore, the treated scars were already mature at the time of the nanofat treatment, therefore ruling out the physiological regenerative process as a possible cause for scar improvement as the natural scar formation process is usually terminated after 18 to 24 months. Further research is of course necessary in order to clarify whether scar age and etiology has any sort of influence on nanofat results. Additionally, the amount of nanofat needed to be effective still remains unclear and has to be defined in the future.

Limitations of this study are the fact that it is a retrospective, nonrandomized case series. Patients were not compared to a control group that was treated with other injectables or surgery. The evaluation of the results was performed clinically and based on the patient's satisfaction, without any objective measurement (e.g., histology). Additionally, the evaluation of patient satisfaction conducted by live interviews with a physician may represent a potential limitation of the study.

With that, we believe that this study provides essential information in terms of the results after nanofat treatment. As of now there only limited data on the clinical results are available, especially as wrinkles and discolorations are scarcely investigated in this field. In order to better characterize the beneficial effects of nanofat injections, a larger prospective study involving a control group with only

saline injections is planned. In addition, further investigations intended to characterize the underlying molecular mechanisms involving metabolomics and proteomics are ongoing.

CONCLUSION

In this study we demonstrated our experience with nanofat for the treatment of scars, wrinkles, and discoloration of the skin. Our results show that nanofat conveys beneficial effects on skin texture and aesthetic appearance. Treated skin seems to regain clinical characteristics similar to normal skin prior to scarring. Nanofat grafting is an effective alternative to the surgical excision of scars without the risk of potential worsening or expensive short-term dermatologic treatments of wrinkles and discoloration. This safe and feasible application, together with the low tissue morbidity, makes it a valuable new tool in the repertoire of every plastic surgeon.

Supplementary Material

This article contains supplementary material located online at www.aestheticsurgeryjournal.com.

Acknowledgements

We would like to thank Michelle McLuckie for her review and assistance during the manuscript preparation process.

Disclosures

The authors declared no potential conflicts of interest with respect to the research, authorship, and publication of this article.

Funding

The authors received no financial support for the research, authorship, and publication of this article.

REFERENCES

1. Ketchum LD, Smith J, Robinson DW, Masters FW. The treatment of hypertrophic scar, keloid and scar contracture by triamcinolone acetonide. *Plast Reconstr Surg*. 1966;38(3):209-218.
2. Berman B, Viera MH, Amini S, Huo R, Jones IS. Prevention and management of hypertrophic scars and keloids after burns in children. *J Craniofac Surg*. 2008;19(4):989-1006.
3. Atiyeh BS. Nonsurgical management of hypertrophic scars: evidence-based therapies, standard practices, and emerging methods. *Aesthetic Plast Surg*. 2007;31(5):468-492; discussion 493.
4. Nouri K, Vidulich K, Rivas MP. Lasers for scars: a review. *J Cosmet Dermatol*. 2006;5(1):14-22.
5. Berman B, Flores F. The treatment of hypertrophic scars and keloids. *Eur J Dermatol*. 1998;8(8):591-595.
6. Mojallal A, Lequeux C, Shipkov C, et al. Improvement of skin quality after fat grafting: clinical observation and an animal study. *Plast Reconstr Surg*. 2009;124(3):765-774.
7. Guisantes E, Fontdevila J, Rodríguez G. Autologous fat grafting for correction of unaesthetic scars. *Ann Plast Surg*. 2012;69(5):550-554.
8. Tonnard P, Verpaele A, Peeters G, Hamdi M, Cornelissen M, Declercq H. Nanofat grafting: basic research and clinical applications. *Plast Reconstr Surg*. 2013;132(4):1017-1026.
9. Neuber GA. Fettransplantation. *Chir Kongr Verhandl Dtsch Ges Chir*. 1893;22:66.
10. Holländer E. Die kosmetische Chirurgie. In: Joseph M, eds. *Handbuch der Kosmetik*. Leipzig: Veit & Comp;1912:669-712.
11. Rigotti G, Marchi A, Galiè M, et al. Clinical treatment of radiotherapy tissue damage by lipoaspirate transplant: a healing process mediated by adipose-derived adult stem cells. *Plast Reconstr Surg*. 2007;119(5):1409-1422; discussion 1423.
12. Klinger M, Marazzi M, Vigo D, Torre M. Fat injection for cases of severe burn outcomes: a new perspective of scar remodeling and reduction. *Aesthetic Plast Surg*. 2008;32(3):465-469.
13. Klinger M, Lisa A, Klinger F, et al. Regenerative Approach to Scars, Ulcers and Related Problems with Fat Grafting. *Clin Plast Surg*. 2015;42(3):345-352, viii.
14. Gutiérrez-Fernández M, Otero-Ortega L, Ramos-Cejudo J, Rodríguez-Frutos B, Fuentes B, Díez-Tejedor E. Adipose tissue-derived mesenchymal stem cells as a strategy to improve recovery after stroke. *Expert Opin Biol Ther*. 2015;15(6):873-881.
15. Richardson SM, Kalamegam G, Pushparaj PN, et al. Mesenchymal stem cells in regenerative medicine: Focus on articular cartilage and intervertebral disc regeneration. *Methods*. 2016;99:69-80.
16. Suzuki E, Fujita D, Takahashi M, Oba S, Nishimatsu H. Adipose tissue-derived stem cells as a therapeutic tool for cardiovascular disease. *World J Cardiol*. 2015;7(8):454-465.
17. Zuk PA, Zhu M, Ashjian P, et al. Human adipose tissue is a source of multipotent stem cells. *Mol Biol Cell*. 2002;13(12):4279-4295.
18. Zhang Q, Liu LN, Yong Q, Deng JC, Cao WG. Intralesional injection of adipose-derived stem cells reduces hypertrophic scarring in a rabbit ear model. *Stem Cell Res Ther*. 2015;6:145.
19. Sultan SM, Stern CS, Allen RJ Jr, et al. Human fat grafting alleviates radiation skin damage in a murine model. *Plast Reconstr Surg*. 2011;128(2):363-372.
20. Bruno A, Delli Santi G, Fasciani L, Cempanari M, Palombo M, Palombo P. Burn scar lipofilling: immunohistochemical and clinical outcomes. *J Craniofac Surg*. 2013;24(5):1806-1814.
21. Pallua N, Baroncini A, Alharbi Z, Stromps JP. Improvement of facial scar appearance and microcirculation by autologous lipofilling. *J Plast Reconstr Aesthet Surg*. 2014;67(8):1033-1037.
22. Osinga R, Menzi NR, Tchang LA, et al. Effects of intersyringe processing on adipose tissue and its cellular components: implications in autologous fat grafting. *Plast Reconstr Surg*. 2015;135(6):1618-1628.

23. Banyard DA, Sarantopoulos CN, Borovikova AA, et al. Phenotypic Analysis of Stromal Vascular Fraction after Mechanical Shear Reveals Stress-Induced Progenitor Populations. *Plast Reconstr Surg*. 2016;138(2):237e-247e.
24. Rohrich RJ, Sorokin ES, Brown SA. In search of improved fat transfer viability: a quantitative analysis of the role of centrifugation and harvest site. *Plast Reconstr Surg*. 2004;113(1):391-395; discussion 396.
25. Almeida KA, Campa A, Alonso-Vale MI, et al. Fraccion vascular stromal tejido adiposo: como obtener células madre y su rendimiento de acuerdo a la topografía de las áreas donantes: estudio preliminar. *Cir Plast Iberolatinoam*. 2008;34:71-77.
26. Hou A, Cohen B, Haimovic A, Elbuluk N. Microneedling: a comprehensive review. *Dermatol Surg*. 2017;43(3):321-339.
27. Aust MC, Fernandes D, Kolokythas P, Kaplan HM, Vogt PM. Percutaneous collagen induction therapy: an alternative treatment for scars, wrinkles, and skin laxity. *Plast Reconstr Surg*. 2008;121(4):1421-1429.
28. Aust MC, Reimers K, Gohritz A, et al. Percutaneous collagen induction. Scarless skin rejuvenation: fact or fiction? *Clin Exp Dermatol*. 2010;35(4):437-439.
29. Fabbrocini G, Fardella N, Monfrecola A, Proietti I, Innocenzi D. Acne scarring treatment using skin needling. *Clin Exp Dermatol*. 2009;34(8):874-879.
30. Nassar A, Ghomey S, El Gohary Y, El-Desoky F. Treatment of striae distensae with needling therapy versus microdermabrasion with sonophoresis. *J Cosmet Laser Ther*. 2016;18(6):330-334.



The Help You Need
Is Finally
Here.

**SMART
BEAUTY
GUIDE**

BROUGHT TO YOU BY
THE AMERICAN SOCIETY FOR
AESTHETIC PLASTIC SURGERY

Prospects for Your Practice
Products Patients Want
Content You Trust

www.smartbeautyguide.com

American Society for Aesthetic Plastic Surgery
11262 Monarch St., Garden Grove, CA 92841-1441
800.364.2147 • 562.799.2356