



## Use of a controlled subdermal radio frequency thermistor for treating the aging neck: Consensus recommendations

Brian M. Kinney, Anneke Andriessen, Barry E. DiBernardo, Jason Bloom, Dennis F. Branson, Richard D. Gentile, David J. Goldberg, Paul Z. Lorenc, Mark Nestor & Douglas Wu

To cite this article: Brian M. Kinney, Anneke Andriessen, Barry E. DiBernardo, Jason Bloom, Dennis F. Branson, Richard D. Gentile, David J. Goldberg, Paul Z. Lorenc, Mark Nestor & Douglas Wu (2017) Use of a controlled subdermal radio frequency thermistor for treating the aging neck: Consensus recommendations, *Journal of Cosmetic and Laser Therapy*, 19:8, 444-450, DOI: [10.1080/14764172.2017.1343952](https://doi.org/10.1080/14764172.2017.1343952)

To link to this article: <http://dx.doi.org/10.1080/14764172.2017.1343952>



Accepted author version posted online: 30 Jun 2017.  
Published online: 30 Jun 2017.



Submit your article to this journal [↗](#)



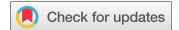Article views: 51



View related articles [↗](#)



View Crossmark data [↗](#)



## Use of a controlled subdermal radio frequency thermistor for treating the aging neck: Consensus recommendations

Brian M. Kinney<sup>a\*</sup>, Anneke Andriessen<sup>b,c</sup>, Barry E. DiBernardo<sup>d</sup>, Jason Bloom<sup>e</sup>, Dennis F. Branson<sup>f</sup>, Richard D. Gentile<sup>g</sup>, David J. Goldberg<sup>h</sup>, Paul Z. Lorenc<sup>i,j</sup>, Mark Nestor<sup>k,l</sup>, and Douglas Wu<sup>m</sup>

<sup>a</sup>Department of Plastic Surgery, USC School of Medicine, Beverly Hills, CA, USA; <sup>b</sup>Radboudumc, Radboud Academie, Nijmegen, Netherlands; <sup>c</sup>Andriessen Consultanta, Malden, Netherlands; <sup>d</sup>Surgery, Plastic Surgery Division, University of Medicine & Dentistry of New Jersey, Montclair, NJ, USA; <sup>e</sup>Main Line for Laser Surgery, Ardmore, OK, USA; <sup>f</sup>Aesthetic, Plastic and Reconstructive Surgery, Fayetteville, NY, USA; <sup>g</sup>Facial Plastic & Aesthetic Laser Center & The MIA Center, Boardman, OH, USA; <sup>h</sup>Skin Laser & Surgery Specialists, Westwood, CA, USA; <sup>i</sup>Lorenc Aesthetic Plastic Surgery Center, New York, USA; <sup>j</sup>Lenox Hill Hospital, New York, NY, USA; <sup>k</sup>School of Medicine, Dermatology and Cutaneous Surgery, University of Miami, Miami, FL, USA; <sup>l</sup>Center for Cosmetic Enhancement and Center of Cosmetic Research, Aventura, FL, USA; <sup>m</sup>Cosmetic Laser Dermatology, San Diego, CA, USA

### ABSTRACT

**Introduction:** A new temperature-controlled device has been used as a percutaneous radio frequency probe to treat lax submental and other facial areas. It has significant advantages over other esthetic devices as it provides the dual benefit of fat lipolysis and skin tightening. Our goal here is to present consensus recommendations for treating the aging neck. **Methods:** A panel of 11 expert physicians convened in Dallas, Texas, on October 15, 2016 to arrive at a consensus on the best current practice for submental skin tightening and contour improvement. Prior to the meeting, a comprehensive review of the literature was performed and a survey was sent to esthetic dermatologists and plastic surgeons who were queried about various aspects of neck rejuvenation. **Results:** The literature search revealed 10 different technologies for neck rejuvenation evaluated in double-blind ( $n = 2$ ) and single-blind ( $n = 1$ ) clinical trials and other clinical evaluations ( $n = 21$ ). The survey was sent *via* an email to 1248 individuals and was completed by 92 respondents. Review of the data and discussion by meeting attendees generated eight consensus recommendations. **Discussion:** Subdermal monopolar radio frequency represents an effective means for disrupting fat volume and skin tightening of the face, neck, and jawline. For suitable patients, this treatment can be used to achieve significant esthetic improvements.

### ARTICLE HISTORY

Received 26 March 2017  
Accepted 14 June 2017

### KEYWORDS

Esthetic dermatology;  
consensus  
recommendations; neck  
rejuvenation; subdermal  
radio frequency thermistor;  
submental skin tightening;  
temperature-controlled



### Introduction

Facial aging is the result of intrinsic factors including hormonal changes and free radical-induced damage, and extrinsic factors such as the effects of gravity, sun exposure, and smoking (1). Common features of the aging neck include increased submental fat, platysmal banding, and redundant dyspigmented skin (2). Since the contour of the neck is a significant aspect in facial esthetics, creating a more acute cervicomenal angle, distinct mandibular border, mobile, supple and tight muscle, and fibro-septal subcutaneous tissues, homogeneous skin tone, and smoother texture are important factors for achieving a more youthful appearance. Historically, these unwanted changes in neck appearance were treated using surgery and liposuction (3–7); however, numerous non- and minimally invasive procedures have been developed to provide non-surgical approaches for cervicomenal rejuvenation and fatty recontouring.

As the combination of different intrinsic and extrinsic factors can result in a wide range of clinical presentations (2), esthetic treatments need to be customized accordingly. Selecting the right procedure for appropriate patients that will effectively meet the esthetic goals and expectations of each

patient is the core of successful neck rejuvenation. In addition to tightening lax submental skin, these procedures involve in the removal of unwanted submental fat, requiring a thorough understanding of neck anatomy. Supraplatysmal fat is found deep in the skin and superficial to the platysma muscle, and distributed between suprahyoid and infrahyoid compartments (8). Subplatysmal fat is found in three compartments, central, medial, and lateral, which border one another to form the subplatysmal fat layer (9). It is also important to know the location of nerves and to perform nerve mapping prior to performing esthetic procedures to avoid injuries (10,11).

Among the various minimally invasive therapies which are now available for treating the aging neck, a novel temperature-controlled device uses a percutaneous radio frequency probe to achieve submental skin tightening (THERMItight<sup>®</sup>; Thermi<sup>™</sup>, Irving, TX) (12,13). This device appears to have significant advantages over other esthetic devices used to improve submental areas as it provides the dual benefit of fat lipolysis and foreshortening of the platysma, fascia, and skin, which lifts the area. The objective of this paper is to gain a better understanding of the available

**CONTACT** Brian M. Kinney  [brian@briankinney.com](mailto:brian@briankinney.com)  Department of Plastic and Reconstructive Surgery, USC School of Medicine, 120 South Spalding Drive, Suite 330, Beverly Hills, CA 90212, USA.

\*Dr. Brian M. Kinney is the Medical Director of ThermiAesthetics.

Color versions of one or more of the figures in the article can be found online at [www.tandfonline.com/ijcl](http://www.tandfonline.com/ijcl).

procedures used for skin tightening and contour improvement of the submental area.

## Literature search

A systematic literature search was performed on August 1–3, 2016 (PubMed.gov; US National Library of Medicine, National Institutes of Health). Searches were prospectively limited to English language articles published between January, 2005 and August, 2016. Review articles were excluded. Medical subject heading terms used in various combinations included tissue tightening, skin tightening, skin laxity, neck tightening, neck, submental, contour improvement, under-chin, jowls, radio frequency, dermal heating, radio frequency, ultrasound, deoxycholic acid, laser, infrared, cryolipolysis, and non-ablative.

Identified publications that met the selection criteria were reviewed based on clinical relevance and level of evidence using a consensus process and pre-established criteria. The quality of evidence used for clinical recommendations was graded using a three-point scale (14): (I) good-quality patient-oriented evidence, (II) limited-quality patient-oriented evidence, and (III) other evidence including consensus guidelines, opinion, case studies, or disease-oriented evidence. Clinical recommendations (14) were based on (A) consistent and good-quality patient-oriented evidence, (B) inconsistent or limited-quality patient-oriented evidence, and (C) consensus, opinion, case studies, or disease-oriented evidence. A summary of the literature search results is provided in Table 1 and an overview of treatment options and available devices is provided in Table 2.

For all the reviewed treatments, there was only limited-quality patient-oriented evidence (Level II-B) available, except for deoxycholic acid injections which were supported with two randomized double-blind, placebo-controlled studies (Evidence Level I-A) (15,16); however, this type of treatment showed moderate adverse events at the injection site and marginal mandibular nerve paresis which was resolved without sequelae (16).

Temperature-controlled subdermal skin tightening treatment efficacy and safety was supported by two small studies (12,13). Subdermal monopolar radio frequency skin tightening efficacy and safety was supported by three single-treatment studies, one study using six treatments and two open-label studies using two radio frequency treatments (17–21). The use of bipolar radio frequency was supported by one small open-label study (22), which reported mild adverse events. Super-pulsed radio frequency was tested in a cohort study ( $N = 100$ ) with a six-month follow-up. Most subjects in this study (94%) showed a marked improvement with this safe treatment (23). An open-label study on safety and efficacy of pulsed 1440-nm Nd:YAG wavelength and side-firing fiber for subcutaneous fat and skin laxity of the neck in 24 subjects showed a significant improvement in the cervicomentale angle and physician global esthetic improvement scores (24). Four small studies using infrared light (1100–1800 nm) demonstrated facial contour and neck improvements in most treated subjects with only mild or no adverse events reported (25–28). Micro-focused ultrasound treatment efficacy and safety on the submental, submandibular, lower neck, and platysmal areas was evaluated

in six studies (29–34). Although most treated subjects demonstrated improvements, moderate adverse events such as prolonged erythema and mild scabbing were reported. Cryolipolysis was evaluated in a pivotal investigational device exemption study ( $N = 60$ ) (35). A single-treatment cycle was delivered at  $-10^{\circ}\text{C}$  for 60 minutes and an optional second treatment was delivered at six weeks. Independent photo review and ultrasound data indicated marked improvements in the cervicomentale angle.

## Pre-meeting survey

A pre-meeting survey was conducted to gain an understanding of the procedures being used for subdermal skin tightening and contour improvement of the under-chin and jowl areas in medical esthetic practice, and their associated challenges and benefits. An additional goal of the survey was to establish the clinical positioning of treatment using the temperature-controlled device (12,13) based on the experience of current users with respect to its efficacy, optimal dose, frequency of administration, and other procedural details. Other clinical considerations were specific factors that could influence clinical outcomes, contraindications, adverse events, and optimal risk–benefit ratio.

The survey questionnaire was sent *via* an email to 1248 physicians on August 27, 2016 of whom 415 who opened the email and 92 who completed the questionnaire were included in the analysis. The survey respondents described themselves as primarily plastic surgeons (39.13%) and esthetic plastic surgeons (21.74%) working in private practice (71.74%) (Figure 1). Among patients seeking treatment, most (52.17%) were between 45 and 55 years and the majority (59.9%) were considered suitable candidates for treatment with the temperature-controlled device. When physicians were asked to indicate the type of radio frequency technology used for the treatment of fat reduction and skin laxity of the submentum (and jowls) in their practice, the majority (85.9%) used the temperature-controlled subdermal monopolar radio frequency device (Figure 2). Before treatment, surveyed physicians gathered the following patient information: patient age (89–96.7%), degree of skin laxity (96.7%), previous treatment (93.5%), full medical history (88.0%), physical exam (80.4%), history of smoking (79.4%), ethnicity (45.7%), body mass index (41.3%), and other information (13.0%).

Although the respondents had mixed opinions regarding contraindications (Table 3), probe temperature (Table 4), and clinical endpoints, they were generally in agreement that treatment with monopolar temperature-controlled device can safely and effectively achieve skin tightening and fat reduction of submental tissue and jowls (89.1%) and gliding planes (78.3%). The lack of downtime makes this procedure very interesting for esthetic surgeons (83.70%). Temperature-controlled treatment delivers comprehensive skin tightening, which takes place over time and involves submuscular aponeurotic system (SMAS), dermal and hypodermal collagen remodeling (95.65%), and skin tightening, which continues to be evident six months after a single treatment (85.87%).

Table 1. Summary of the literature search results.

Treatment/device	Study design	Subjects (N)	Results	Adverse events
Thermistor-controlled subdermal skin tightening	Retrospective review of subjects undergoing thermistor-controlled subdermal skin tightening <i>via</i> percutaneous radio frequency (13). Retrospective study on the device used for submental skin tightening of under-chin and jowls (12). The thermistor probe was used to treat 3.0 cm <sup>2</sup> every 2 minutes. The clinical endpoint was an epidermal temperature of 42°C. Retrospective study assessed the overall efficacy and satisfaction of subjects who underwent a single SMRF treatment to the face, neck, jawline, alone or in combination (17). Cohort study treating mild-to-moderate cheek (n = 30) or neck laxity (n = 20) with one SMRF treatment (18). Evaluation of six radio frequency treatments every 15 days, every month, and every two months, all for two consecutive sessions (19).	18 35 35	Two infrared thermometers recorded mean temperatures of 43.6 and 38.2°C supporting its use for skin tightening. Using a 4.0-point skin laxity scale, the combined mean change in baseline skin laxity scores was -0.78 (p < 0.0001). At 180 days post-treatment, 77% of the subjects reported improvement, and 64% reported satisfaction.	None None None
Subsurface monopolar radio frequency (SMRF) skin tightening	Open label study on two radio frequency treatments to the face and neck one month apart (20). Evaluation of multiple pass, low fluence treatment algorithm for lower face laxity (21).	50 17 49 66	Significant improvement in cheek and neck skin laxity was observed in most patients. At four weeks post-treatment, patient-reported mean improvement of 25–30% was noted and prior to the last treatment, the mean improvement was 48–50%, decreasing to 46 and 30% at six months after the final treatment. Noted improvements: overall, 74% of the subjects; skin condition, 85%; skin laxity, 81%. At six months, improvement in overall appearance was noted in 92% of the subjects using the Leal Laxity Classification system and 84% with independent photographic assessments. At six weeks, 71% noted improvement and 29% showed mild improvement.	Mild erythema, edema and dysesthesia. Mild None None
Bipolar radio frequency	Open label study. Subjects underwent a series of four to six weekly treatments (22). Cohort study face and neck laxity (23).	14 100 24	At six months, improvement was noted in 94% of the subjects. At six months post-treatment, 79% of the subjects had significant improvement in the Cervicofacial Angle Score (p < 0.001) and 79% demonstrated an improvement on the GAIS. After a mean (SD) of 2.1 (0.9) treatments and mean follow-up interval of 1.9 (1) months, the mean baseline laxity grade of 2.9 (0.5) decreased to 2.5 (0.6) (p < 0.0001).	Mild Mild Mild
Super-pulsed radio frequency 1440-nm Nd:YAG device	Open label study on safety and efficacy of pulsed 1440-nm Nd:YAG wavelength and side-firing fiber for subcutaneous fat and skin laxity of the neck in subjects 40–65 years old (24). Prospective study on three treatments with incoherent infrared (1100–1800 nm) light at two- to four-week intervals, evaluating safety, efficacy, and tolerability for treating facial and neck skin laxity (25). Evaluation on efficacy of 1100–1800 nm infrared given as two treatments one month apart for facial and cervical skin tightening (26).	22 10	After three months, physicians noted 10% improvement and patient reported 32% improvement for the cheeks and 20% for the neck. Subjects reported mild (23%), moderate (15%), and significant (54%) improvements at three months. By objective assessment, 41% of the subjects had some degree of improvement of the treated side. At six months, 57% showed market improvements and 28% mild.	None Blistering (n = 1) None
Infrared light	Prospective, split-face, single-blinded study on safety and efficacy using the device for skin tightening (27). The untreated side served as a control. Treatment was performed twice with a four-week interval between the treatments. Prospective, open-label study assessed the clinical efficacy and safety of three treatment sessions four weeks apart (28). Evaluation of treatment at two focal depths on the submental, submandibular, lower neck, and platysmal areas (29). Prospective, open-label pilot using a dual depth treatment with a vectored pattern (30).	13 21 71	At six months, all patients showed improvements. Evaluation at 90 days, 180 days, and one year (GAIS) showed that 90–100% of the subjects had improvements at 90 and 180 days and 95% at one year. Evaluation (GAIS) at 90 and 180 days showed that 81.3 and 77.8% of the subjects achieved improvements, respectively. Blinded reviewers observed improvement in skin laxity in 58.1% of the subjects and overall improvement in skin laxity in 63.6%. Three moderately severe prolonged cases of erythema with mild scabbing (n = 1) resolved after 90 days without sequelae. At 90 days, 80% of the 10 evaluable subjects showed improvements.	Mild pain and edema, episodes of blistering (n = 7) None
Micro-focused ultrasound	Retrospective clinical evaluation (31). Prospective, non-randomized clinical trial (32). Open-label, non-randomized trial on safety (33). Open-label study treating face and neck with two transducers with focal depths of 3.0 and 4.5 mm (34).	20 45 103 52 12		Mild Moderate pain Mild-moderate erythema None

(Continued)

Table 1. (Continued).

Treatment/device	Study design	Subjects (N)	Results	Adverse events
Deoxycholic acid injections	Phase 3, randomized, placebo-controlled study on efficacy and safety for moderate-to-severe submental fat reduction (15). Phase 3, randomized, double-blind, placebo-controlled study assessed the efficacy and safety for moderate or severe submental fat treatment (16).	Study treatment (n = 258), placebo (n = 258) Study treatment (n = 256), placebo (n = 250).	At week 12, one or more grades of improvement were achieved by 66.5% study group subjects vs. 22.2% in the placebo group (p < 0.001). At week 12, one or more grades of improvement were achieved by 70% study group subjects vs. 18.6% in the placebo group (p < 0.001).	Moderate at the injection site in both groups Moderate at the injection site in both groups. Marginal mandibular nerve paresis (4.3%). All resolved without sequelae. Moderate at the injection site in both groups
Cryolipolysis	Post hoc study assessed the efficacy and safety of deoxycholic acid for submental fat reduction by a pooled analysis of two large phase 3 studies (36). Pivotal investigational device exemption study. A single treatment cycle was delivered at -10°C for 60 minutes. An optional second treatment was delivered at six weeks (35).	- 60	Clinician-reported ≥1-point improvement in SMF: 58.8 and 63.8% of the patients who received deoxycholic acid, and 28.6% of the placebo recipients (p < 0.001). Independent photo review from three blinded physicians identified 91% of the baseline photographs. Ultrasound data indicated mean fat layer reduction of 2.0 mm.	None

GAIS, global aesthetic improvement scale.

### Expert panel composition

A consensus panel of 11 physicians who are experts in esthetic medicine was convened in Dallas, Texas, on October 15, 2016. This evidence-based approach (14) included a review of the researched literature and the results of the pre-meeting survey on submental skin tightening and contour improvement of the aging neck. Consensus of the panel on best current practice and clinical recommendations for rejuvenating the appearance of the aging neck was defined as two-thirds of the majority, obtained *via* a blinded Delphi process. The recommendations and their clinical interpretation were outlined in a clinical treatment algorithm for the temperature-controlled device.

### Clinical treatment algorithm

A review of available literature, survey responses, and group discussions reaching consensus resulted in a clinical algorithm for the use of temperature-controlled subdermal monopolar radio frequency treatment for skin laxity and fat reduction of the face, neck, and jawline (Figure 3). The subdermal monopolar radio frequency device is a precise and controlled subdermal skin- and connective-tissue-tightening device that uses a percutaneous radio frequency treatment probe (12,13). When treating fat, lipolysis may occur when specific temperatures are achieved. Similarly, when treating lax skin, and the fibro-septal network, the delivery of thermal energy causes denaturation and contraction of collagen within seconds with subsequent *de novo* regeneration of collagen and tissue remodeling over weeks to months. Thus, subdermal monopolar radio frequency represents an effective modality for disrupting fat volume and achieving skin tightening of the face, neck, and jawline. It improves contours by tightening the skin, fibro-septal network, and fascia and treating unwanted fat accumulation in the neck and jowl. The mean treatment time with the device is 19 minutes (range: 8–38 minutes) for the submentum and the bilateral neck anterior to the sternocleidomastoid. Treatment times for 25–38 minutes yield optimal results. Survey results suggest that there is an energy delivery threshold, above which a higher percentage of subjects report satisfaction. Adverse events may include pain during or after treatment, edema, bruising, burns, numbness, nerve impairment, nodules or induration and scarring. Burns usually resolve without sequelae.

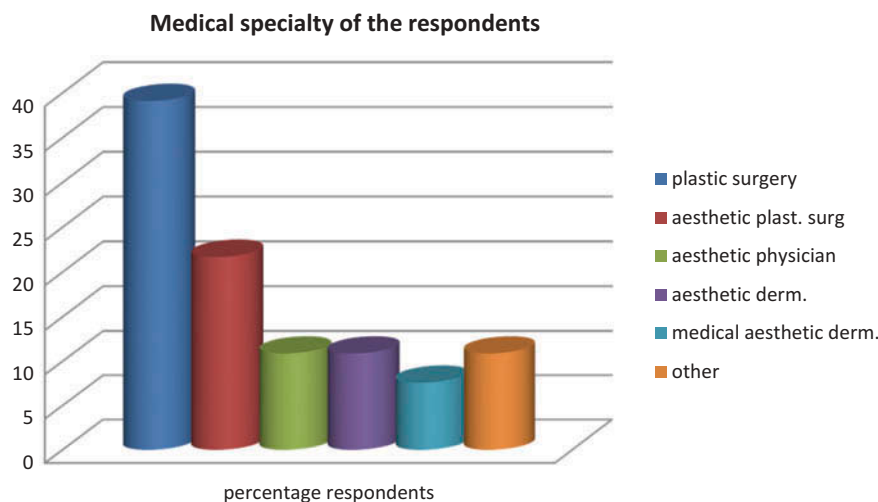
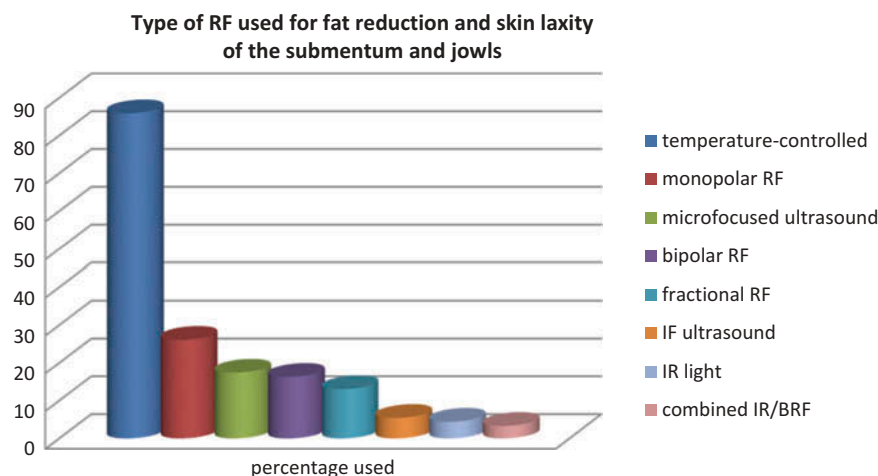
### Limitations

Limitations of this work include a small number of randomized, controlled studies of non- and minimally invasive techniques for the treatment of lax submental areas upon which comparisons were made. In addition, there may have been a bias among the survey respondents toward those physicians using the temperature-controlled subdermal monopolar radio frequency device.



**Table 2.** Treatment of the aging neck.

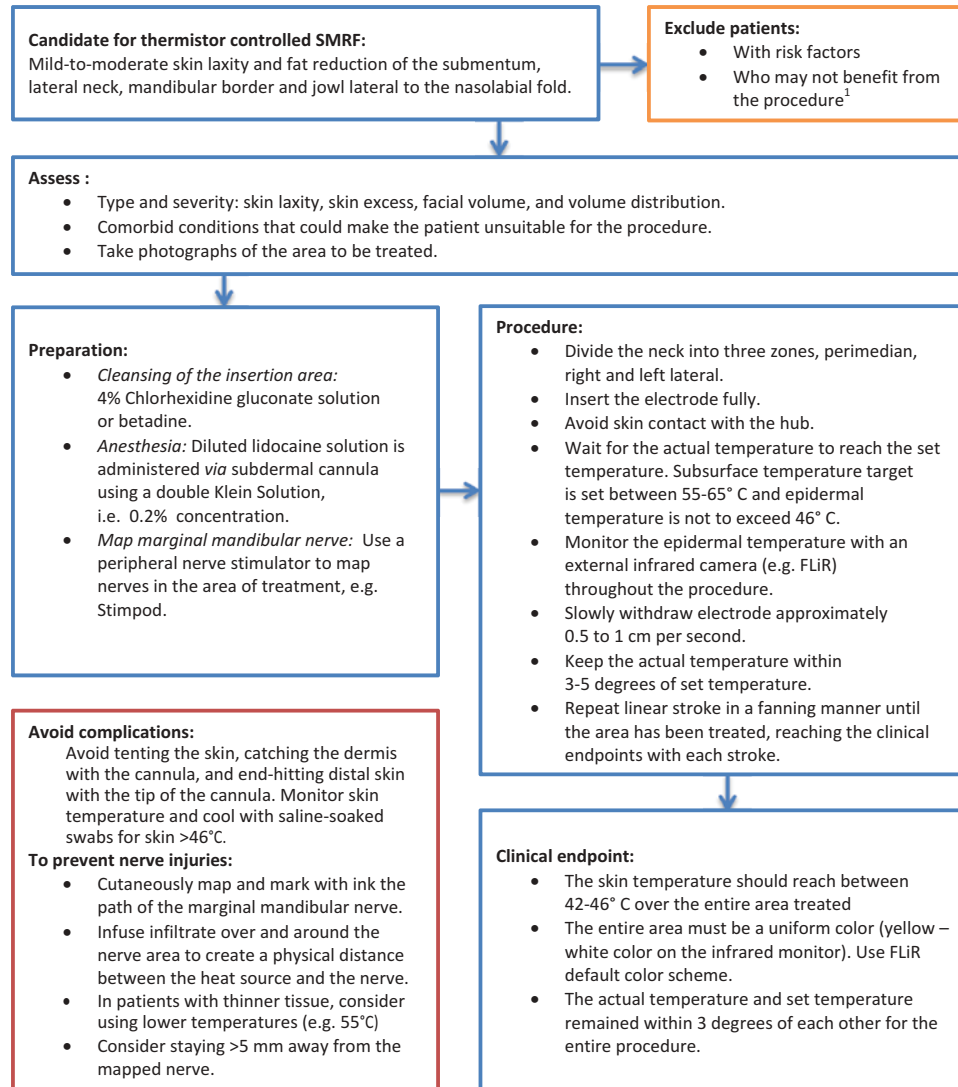
Technology	Treatment
Thermistor-controlled subdermal skin tightening <i>via</i> percutaneous radio frequency (THERMtight®)	One session. The thermistor probe was used to treat 3.0 cm <sup>2</sup> every 2 minutes. The clinical endpoint was an epidermal temperature of 42°C.
Subsurface monopolar radio frequency skin tightening (Thermage®/ThermaCool®)	One session as a stand alone or in combination with other treatments.
Monopolar radio frequency for skin tightening (Pelleve®)	Six radio frequency treatments administered every 15 days for two consecutive sessions, every month for two consecutive sessions, and every two months for two consecutive sessions.
Bipolar radio frequency for skin tightening (Aluma™)	Series of four to six weekly treatments.
Super-pulsed radio frequency for skin tightening (Dermalift®)	Non-ablative super-pulsed radio frequency in one session.
1440nm Nd:YAG device with the side-firing fiber (Cellulaze™)	Laser lipolysis of the submental and anterior cervical areas using a mean of 1205 J per 5 × 5 cm <sup>2</sup> area with a maximum internal temperature setting of 47°C.
Infrared light for skin tightening (Titan®)	One to three treatments with incoherent infrared (1100–1800 nm) light at two- to four-week intervals.
Micro-focused ultrasound for skin tightening (Ulthera®)	Micro-focused ultrasound at two focal depths.
Deoxycholic acid for submental fat reduction (Kybella®)	One session of injections.
Cryolipolysis for reduction of submental fat (CoolSculpting® System)	A single treatment cycle was delivered at –10°C for 60 minutes.

**Figure 1.** Medical specialty of survey respondents.**Figure 2.** Type of radio frequency used by survey respondents. Radio frequency (RF); intense focused ultrasound (IF ultrasound); infrared light (IR); bipolar radio frequency (BRF).**Table 3.** Survey results: contraindications.

Contraindications	Strongly disagree	Disagree	Neutral	Agree	Strongly agree
Pregnancy	4 (4.4)	6 (6.5)	13 (14.1)	37 (40.2)	32 (34.8)
External or internal pacemakers	1 (1.1)	9 (9.8)	14 (15.2)	29 (31.5)	39 (42.4)
Implantable defibrillators	1 (1.1)	7 (7.6)	10 (10.9)	33 (35.9)	41 (44.6)
Cochlear implants	1 (1.1)	7 (7.6)	33 (29.4)	27 (29.4)	24 (26.1)

**Table 4.** Survey results: probe, epidermis, and fat layer temperatures.

Probe temperature in the superficial skin layer is		Epidermis temperature is kept between		The temperature to treat the fat layer in a deeper plane is between	
°C	n (%)	°C	n (%)	°C	n (%)
30–40	1 (1.1)	40–41	5 (5.4)	30–40	0
40–45	12 (13.0)	42–43	29 (31.5)	40–45	2 (2.2)
45–50	6 (6.5)	43–44	35 (38.0)	45–50	10 (10.9)
50–60	31 (33.7)	45–46	18 (19.6)	70–75	52 (56.5)
60–65	27 (29.4)	>45	5 (5.4)	>75	0
65–70	8 (8.7)	0	0	Other	28 (30.4)
70–75	0	0	0	0	0
>75	0	0	0	0	0
Other	7 (7.6)	0	0	0	0



**Figure 3.** Algorithm for temperature-controlled subdermal monopolar radio frequency. Subsurface monopolar radio frequency (SMRF). <sup>1</sup>Women during pregnancy, collagen vascular diseases, autoimmune diseases, acute infections, patients with cochlear and neurostimulator implants, and patients with morbid conditions that could make them unsuitable for the procedure. For patients with an external pacemaker, implantable defibrillator, or monitoring equipment, the attending cardiologist should be consulted prior to the procedure. All implanted devices should be evaluated for contraindications from the manufacturer. When indicated, consult primary care physician. <sup>2</sup>Higher temperatures may be targeted in individual circumstances.

**Conclusion**

The use of subdermal monopolar radio frequency has emerged as a safe and effective means for treating the aging neck. It has significant advantages over other esthetic

devices as it provides the triad benefit of disrupting fat volume and SMAS, and skin tightening of the face, neck, and jawline. For suitable patients, this treatment can be used to achieve significant esthetic improvements of the aging neck.

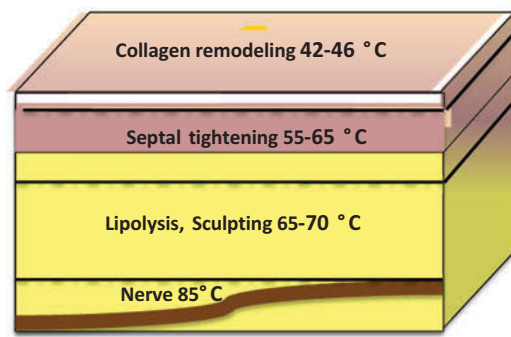


Figure 4. Temperature and treatment effect on various tissue types.

## Acknowledgments

The authors acknowledge the guidance of RBC Consulting, Miami Beach, FL, during the research and preparation of this consensus document.

## References

- Park DM. Total facelift: forehead lift, midface lift, and neck lift. *Arch Plast Surg*. 2015;42:111–125.
- Dibernardo BE. The aging neck: a diagnostic approach to surgical and nonsurgical options. *J Cosmet Laser Ther*. 2013;15:56–64.
- Daher JC. Closed platysmotomy: a new procedure for the treatment of platysma bands without skin dissection. *Aesthetic Plast Surg*. 2011;35:866–877.
- Kim BJ, Choi JH, Lee Y. Development of facial rejuvenation procedures: thirty years of clinical experience with face lifts. *Arch Plast Surg*. 2015;42:521–531.
- Auersvald A, Auersvald LA, Oscar Uebel C. Subplatysmal necklift: a retrospective analysis of 504 patients. *Aesthet Surg J*. 2016;Jun 29 [Epub ahead of print].
- Theodorou S, Chia C. Radiofrequency-assisted liposuction for arm contouring: technique under local anesthesia. *Plast Reconstr Surg Glob Open*. 2013;1:e37.
- Keramidas E, Rodopoulou S. Radiofrequency-assisted liposuction for neck and lower face adipodermal remodeling and contouring. *Plast Reconstr Surg Glob Open*. 2016;4:e850.
- Larson JD, Tierney WS, Ozturk CN, Zins JE. Defining the fat compartments in the neck: a cadaver study. *Aesthet Surg J*. 2014;34:499–506.
- Rohrich RJ, Pessa JE. The subplatysmal supramylohyoid fat. *Plast Reconstr Surg*. 2010;126:589–595.
- Dingman RO, Grabb WC. Surgical anatomy of the mandibular ramus of the facial nerve based on the dissection of 100 facial halves. *Plast Reconstr Surg Transplant Bull*. 1962;29:266–272.
- Baker DC, Conley J. Avoiding facial nerve injuries in rhytidectomy. Anatomical variations and pitfalls. *Plast Reconstr Surg*. 1979;64:781–795.
- Key DJ. Integration of thermal imaging with subsurface radiofrequency thermistor heating for the purpose of skin tightening and contour improvement: a retrospective review of clinical efficacy. *J Drugs Dermatol*. 2014;13:1485–1489.
- Key DJ. Comprehensive thermoregulation for the purpose of skin tightening using a novel radiofrequency treatment device: a preliminary report. *J Drugs Dermatol*. 2014;13:185–189.
- AGREE. Appraisal of guidelines for research & evaluation. The AGREE Research Trust, 2013. Available: [www.agreertrust.org](http://www.agreertrust.org). Accessed October 2016.
- Humphrey S, Sykes J, Kantor J, Bertucci V, Walker P, Lee DR, et al. ATX-101 for reduction of submental fat: a phase III randomized controlled trial. *J Am Acad Dermatol*. 2016;75:788–797.
- Jones DH, Carruthers J, Joseph JH, Callender VD, Walker P, Lee DR, et al. REFINE-1, a multicenter, randomized, double-blind,

- placebo-controlled, phase 3 trial with ATX-101, an injectable drug for submental fat reduction. *Dermatol Surg*. 2016;42:38–49.
- Dendle J, Wu DC, Fabi SG, Melo D, Goldman MP. A Retrospective evaluation of subsurface monopolar radiofrequency for lifting of the face, neck, and jawline. *Dermatol Surg*. 2016;42:1261–1265.
- Alster TS, Tanzi E. Improvement of neck and cheek laxity with a nonablative radiofrequency device: a lifting experience. *Dermatol Surg*. 2004;30:503–507.
- Taub AF, Tucker RD, Palange A. Facial tightening with an advanced 4-MHz monopolar radiofrequency device. *J Drugs Dermatol*. 2012;11:1288–1294.
- Chippis LK, Bentow J, Prather HB, So JJ, Schouest JM, Ozog DM, et al. Novel nonablative radio-frequency rejuvenation device applied to the neck and jowls: clinical evaluation and 3-dimensional image analysis. *J Drugs Dermatol*. 2013;12:1215–1218.
- Bogle MA, Uebelhoer N, Weiss RA, Mayoral F, Kaminer MS. Evaluation of the multiple pass, low fluence algorithm for radiofrequency tightening of the lower face. *Lasers Surg Med*. 2007;39:210–217.
- Nelson AA, Beynet D, Lask GP. A novel non-invasive radiofrequency dermal heating device for skin tightening of the face and neck. *J Cosmet Laser Ther*. 2015;17:307–312.
- Sharad J. Nonablative facelift in Indian skin with superpulsed radiofrequency. *Indian Dermatol Online J*. 2011;2:6–9.
- Sarnoff DS. Evaluation of the safety and efficacy of a novel 1440 nm Nd: YAG laser for neck contouring and skin tightening without liposuction. *J Drugs Dermatol*. 2013;12:1382–1388.
- Alexiades-Armenakas M. Assessment of the mobile delivery of infrared light (1100–1800 nm) for the treatment of facial and neck skin laxity. *J Drugs Dermatol*. 2009;8:221–226.
- Carniol PJ, Dzopa N, Fernandes N, Carniol ET, Renzi AS. Facial skin tightening with an 1100–1800 nm infrared device. *J Cosmet Laser Ther*. 2008;10:67–71.
- Chan HH, Yu CS, Shek S, Yeung CK, Kono T, Wei WI. A prospective, split face, single-blinded study looking at the use of an infrared device with contact cooling in the treatment of skin laxity in Asians. *Lasers Surg Med*. 2008;40:146–152.
- Chua SH, Ang P, Khoo LS, Goh CL. Nonablative infrared skin tightening in Type IV to V Asian skin: a prospective clinical study. *Dermatol Surg*. 2007;33:146–151.
- Baumann L, Zelickson B. Evaluation of micro-focused ultrasound for lifting and tightening neck laxity. *J Drugs Dermatol*. 2016;15:607–614.
- Werschler WP, Werschler PS. Long-term efficacy of micro-focused ultrasound with visualization for lifting and tightening lax facial and neck skin using a customized vectoring treatment method. *J Clin Aesthet Dermatol*. 2016;9:27–33.
- Fabi SG, Goldman MP. Retrospective evaluation of micro-focused ultrasound for lifting and tightening the face and neck. *Dermatol Surg*. 2014;40:569–575.
- Oni G, Hoxworth R, Teotia S, Brown S, Kenkel JM. Evaluation of a microfocused ultrasound system for improving skin laxity and tightening in the lower face. *Aesthet Surg J*. 2014;34:1099–110.
- Harris MO, Sundaram HA. Safety of microfocused ultrasound with visualization in patients with Fitzpatrick skin phototypes III to VI. *JAMA Facial Plast Surg*. 2015;17:355–357.
- Lee HS, Jang WS, Cha YJ, Choi YH, Tak Y, Hwang E, et al. Multiple pass ultrasound tightening of skin laxity of the lower face and neck. *Dermatol Surg*. 2012;38:20–27.
- Kilmer SL, Burns AJ, Zelickson BD. Safety and efficacy of cryolipolysis for non-invasive reduction of submental fat. *Lasers Surg Med*. 2016;48:3–13.
- McDiarmid J, Ruiz JB, Lee D, Lippert S, Hartisch C, Havlickova B. Results from a pooled analysis of two European, randomized, placebo-controlled, phase 3 studies of ATX-101 for the pharmacologic reduction of excess submental fat. *Aesthetic Plast Surg*. 2014;38:849–860.