

Nanofat Grafting: Basic Research and Clinical Applications

Patrick Tonnard, M.D.
 Alexis Verpaele, M.D.
 Geert Peeters, M.D.
 Moustapha Hamdi,
 M.D., Ph.D.
 Maria Cornelissen, Ph.D.
 Heidi Declercq, Ph.D.
Ghent and Brussels, Belgium



Background: The indications for fat grafting are increasing steadily. In microfat grafting, thin injection cannulas are used. The authors describe their experience of fat injection with even thinner injection needles up to 27 gauge. The fat used for this purpose is processed into “nanofat.” Clinical applications are described. Preliminary results of a study, set up to determine the cellular contents of nanofat, are presented.

Methods: Nanofat grafting was performed in 67 cases to correct superficial rhytides, scars, and dark lower eyelids. Three clinical cases are described. In the research study, three fat samples were analyzed. The first sample was a classic lipoaspirate (macrofat). The second sample was microfat, harvested with a multiport small-hole cannula. The third was microfat processed into nanofat. Processing consisted of emulsification and filtering of the lipoaspirate. Fat samples were analyzed for adipocyte viability. Cells from the stromal vascular fraction and the CD34⁺ subfraction were quantified. The stem cell quality was investigated by culturing the cells in standard and adipogenic media.

Results: No viable adipocytes were observed in the nanofat sample. Adipose-derived stem cells were still richly present in the nanofat sample. Cell cultures showed an equal proliferation and differentiation capacity of the stem cells from the three samples. Clinical applications showed remarkable improvements in skin quality 6 months postoperatively. No infections, fat cysts, granulomas, or other unwanted side effects were observed.

Conclusions: Nanofat injections might become a new concept in the lipofilling area. In clinical situations, nanofat seems to be suitable for skin rejuvenation purposes. (*Plast. Reconstr. Surg.* 132: 1017, 2013.)

The first reports on autologous fat grafting were published in the early twentieth century.¹ It became more widely implemented after the introduction of liposuction by Illouz in the 1980s.² Since the standardization of the fat grafting technique by Coleman one decade later, lipofilling has become a very important and valuable tool in plastic surgery.^{3,4} Adipose-derived stem cells were first discovered in 2001.⁵ Since then, much research into these multipotent mesenchymal-derived progenitor cells has been performed. Currently, the applications of adipose-derived stem cell therapy extend far beyond the field of plastic surgery.⁶⁻¹¹

The initial goal of fat grafting was to treat volume losses created by disease, trauma, or aging. Fat was injected with relatively large blunt cannulas (± 2 mm diameter). For delicate areas such as eyelids and lips, smaller injection cannulas became popular. Lipofilling with cannulas as small as 0.7 mm in diameter, also called microfat grafting, has been described.¹²⁻¹⁵ For these indications, fat is harvested with small-hole cannulas

Disclosure: *The authors have no financial interest to declare in relation to the content of this article. No external funding was received.*

Supplemental digital content is available for this article. Direct URL citations appear in the text; simply type the URL address into any Web browser to access this content. Clickable links to the material are provided in the HTML text of this article on the *Journal's* Web site (www.PRSJournal.com).

From Plastic and Aesthetic Surgery, Coupure Centrum for Plastic Surgery Ghent; the Department of Plastic Surgery, University Hospital of Brussels; and the Department of Basic Medical Sciences, Ghent University.

Received for publication December 16, 2012; accepted February 27, 2013.

Copyright © 2013 by the American Society of Plastic Surgeons

DOI: 10.1097/PRS.0b013e31829fe1b0

to obtain a lipoaspirate with smaller fat particles. We previously described microfat grafting in the deep dermal layer of the skin with 23-gauge sharp needles for treatment of fine rhytides in the face.¹⁶

To work even more superficially with still finer sharp needles (27 gauge), the harvested fat was mechanically emulsified and filtered until a liquid suspension was obtained. We call this “nanofat.”

In this article, we describe the technique and report our experience with nanofat grafting. We present three clear clinical cases. In addition, we provide the results of an experimental study to determine the cellular content of the nanofat. The viability of the adipocytes and, more importantly, the number and activity of the adipose-derived stem cells are investigated. The findings of the nanofat sample analysis are compared to two other lipoaspirates obtained by standard fat harvesting techniques.

PATIENTS AND METHODS

Macrofat, Microfat, and Nanofat Harvesting

Liposuction was performed in a 40-year-old female patient during an abdominoplasty procedure. Informed consent to use the lipoaspirate for analysis was obtained from the patient. Fat was harvested from the lower abdomen after infiltration with a modified Klein solution (lidocaine 800 mg/liter and adrenaline 1:1,000,000). The harvested fat was rinsed and filtered through a sterile nylon cloth with 0.5-mm pore size that was mounted over a sterile canister. Two different aspiration cannulas (Fig. 1) were used. Three different lipoaspirate samples were analyzed.

In detail, a high-negative-pressure liposuction procedure was performed using a standard liposuction device. In the first group, a standard 3-mm Mercedes type liposuction cannula with large side holes (2×7 mm) (Fig. 1) was used. In the second and third groups, fat was harvested with a multiport 3-mm cannula with sharp side holes of 1 mm in diameter (Fig. 1); both were obtained from Tulip Medical Products (San Diego, Calif.). After saline rinsing and filtering, no further processing of the lipoaspirates from the first group (called “macrofat”) and second group (called “microfat”) was performed. In the third group, the lipoaspirate was mechanically emulsified after rinsing. Emulsification of the fat was achieved by shifting the fat between two 10-cc syringes connected to each other by a female-to-female Luer-Lok connector. (See Video, Supplemental Digital Content 1, which illustrates how the microfat lipoaspirate

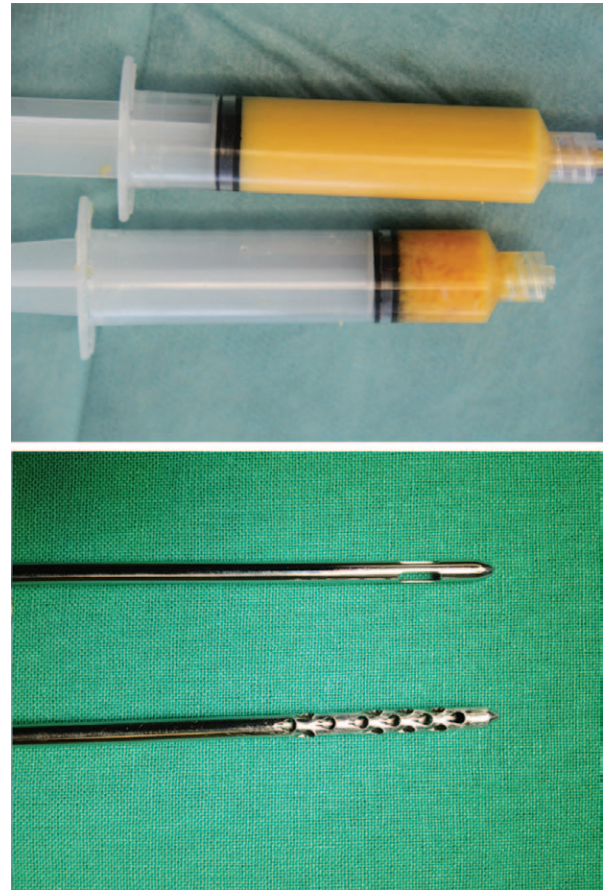
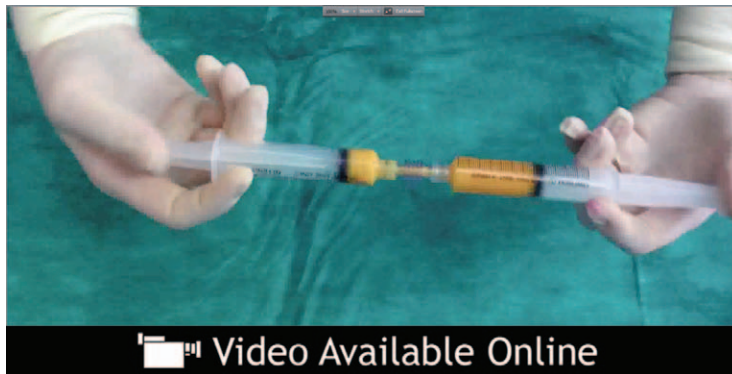

Fig. 1. (Above) Syringe with microfat in a condition before the emulsification process and syringe with a homogeneous fat emulsion after the emulsification process. Note the difference in color and consistency. (Below) A standard 3-mm Mercedes type liposuction cannula with large side holes (2×7 mm) and a 3-mm multiport cannula, containing several sharp side holes of 1-mm diameter. The sharp side holes augment the harvesting yield.

is processed into nanofat, <http://links.lww.com/PRS/A855>.) After 30 passes, the fat changed into an emulsion. At the end of the fragmentation process, the fat became liquid and took on a whitish appearance (Fig. 1). After this emulsification process, the fatty liquid was again filtered over the sterile nylon cloth and the effluent was collected in a sterile recipient (see Video, Supplemental Digital Content 1, <http://links.lww.com/PRS/A855>). This was done to remove the connective tissue remnants that would block the fine needles. This effluent is called “nanofat.”

Patients

Between May of 2010 and September of 2012, nanofat grafting was performed in 67 cases for a variety of indications. It was used for skin rejuvenation purposes in combination with classic microfat grafting or sharp needle intradermal fat



Video 1. Supplemental Digital Content 1 illustrates how the microfat lipoaspirate is processed into nanofat, <http://links.lww.com/PRS/A855>.

grafting.¹⁶ Nanofat grafting was used for the rejuvenation of perioral skin [38 cases (58 percent)], glabellar skin [15 cases (23 percent)], or sun-damaged skin at the breast cleavage [eight cases (11 percent)]. Four scars (6 percent) and two patients with dark lower eyelids (2 percent) were treated with nanofat as well. In all cases, the nanofat was prepared as described above. A 27-gauge needle was mounted on the syringe for superficial intradermal and subdermal injection. Injection was performed until a yellowish discoloration of the skin showed up. [See **Video, Supplemental Digital Content 2**, which demonstrates the injection of nanofat at the lower eyelid (note the yellowish discoloration of the skin after injection), <http://links.lww.com/PRS/A856>; and see **Video, Supplemental Digital Content 3**, which shows the injection of nanofat at the area of the breast cleavage (note the superficial fanwise intradermal injections in which the whole skin area can be covered), <http://links.lww.com/PRS/A857>.] Three clinical examples are described below.

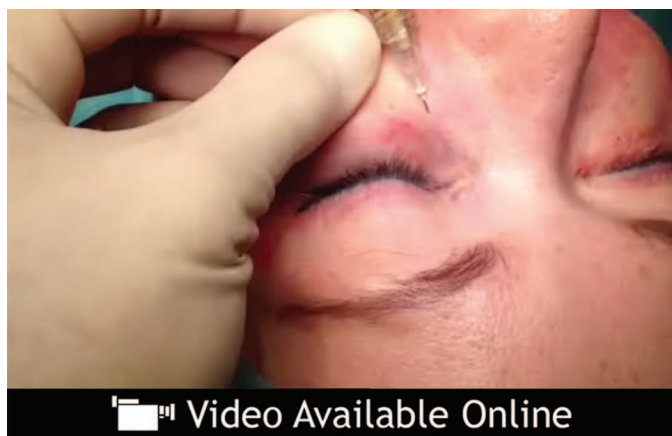Adipocyte Viability

The viability of the lipoaspirates, obtained by the three harvesting techniques, was evaluated using fluorescence microscopy after a live/dead staining. After rinsing the lipoaspirates, 1 ml of phosphate-buffered saline solution supplemented with 2 μ l of calcein AM (1 mg/ml) (AnaSpec, Fremont, Calif.) and 2 μ l of propidium iodide (1 mg/ml) (Sigma-Aldrich, St. Louis, Mo.) was added. Lipoaspirates were incubated for 10 minutes at room temperature, washed twice with phosphate-buffered saline solution, and evaluated by fluorescence microscopy (Olympus inverted Research System Microscope, type U-RFL-T, Cell software; Olympus Belgium, Aartselaar, Belgium).

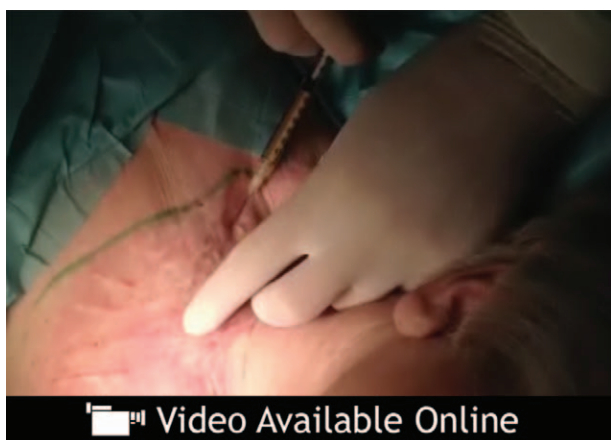
Cell Culture

Stem Cell Isolation

Isolation of the adipose-derived stem cells from the different lipoaspirates (macrofat, microfat, and nanofat) was as follows. An equal aliquot



Video 2. Supplemental Digital Content 2 demonstrates the injection of nanofat at the lower eyelid, <http://links.lww.com/PRS/A856>. Note the yellowish discoloration of the skin after injection.



Video 3. Supplemental Digital Content 3 shows the injection of nanofat at the area of the breast cleavage, <http://links.lww.com/PRS/A857>. Note the superficial fanwise intradermal injections in which the whole skin area can be covered.

of 0.1% collagenase type II (Sigma-Aldrich) in phosphate-buffered saline containing 1% penicillin/streptomycin was added to the lipoaspirates. The mixture was incubated for 45 minutes at 37°C on a gyratory shaker (Laboshake; C. Gerhardt, Königswinter, Germany). Fetal bovine serum was added to a final concentration of 10% to stop enzyme activity followed by centrifugation at 800 rpm for 5 minutes. The overlying fluid and adipose phases were aspirated and discarded. The stromal cell pellet was resuspended in phosphate-buffered saline and filtered through a 70- μ m Falcon cell strainer (Becton Dickinson, Franklin Lakes, N.J.).

The amount of cells was counted with a Türk solution (Merck, Whitehouse Station, N.J.). Half of the stromal vascular fraction was cultivated in a T75 Falcon flask in standard medium [MesenPRO basal medium supplemented with MesenPRO RS growth supplement (Life Technologies, Carlsbad, Calif.) and L-glutamine]. As an additional control experiment, the other half of the stromal vascular fraction was further processed through magnetic-activated cell sorting, with a CD34 kit obtained from Miltenyi Biotec (Auburn, Calif.) according to the company's protocol. Briefly, cells were suspended in magnetic-activated cell-sorting buffer (300 μ l) and Fc receptor-blocking reagent (100 μ l) was added to avoid unspecific CD34 labeling of cells by means of Fc receptors. CD34 microbeads (100 μ l) were added to the cell suspension and incubated for 30 minutes at 4°C. After adding magnetic-activated cell-sorting rinse buffer (5 ml) and centrifuging (5 minutes, 800 rpm), the cell pellet was resuspended in

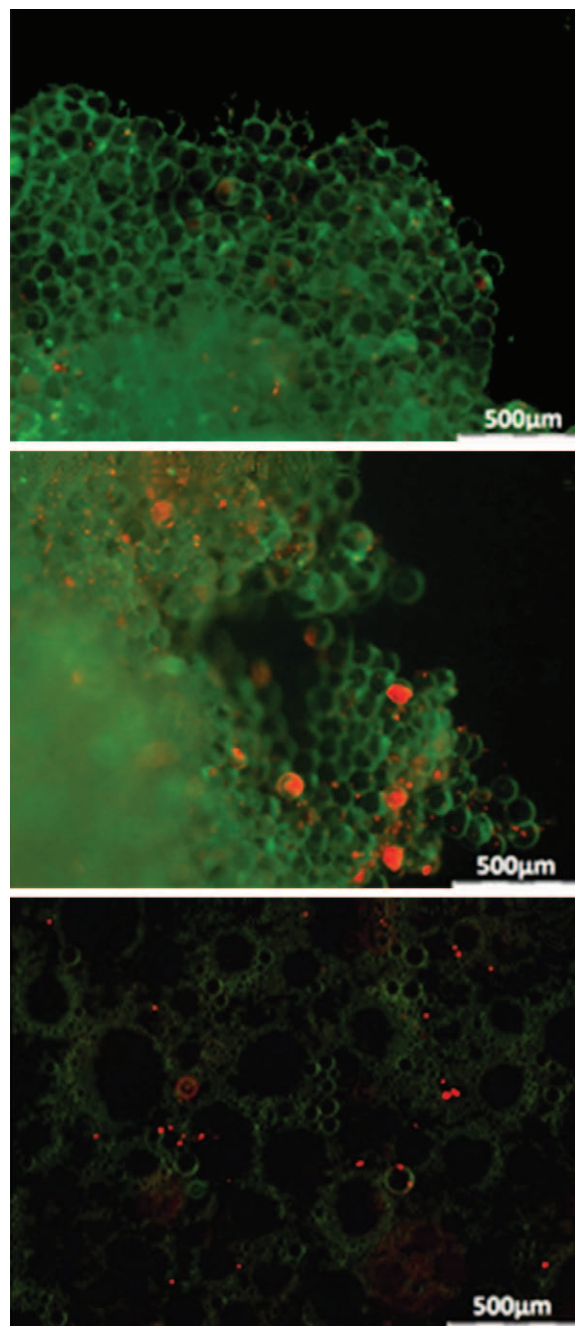


Fig. 2. Fluorescence microscopy of lipoaspirates after calcein AM/propidium iodide staining. (*Above*) Macrofat (lipoaspirate harvested with a 3-mm standard cannula). (*Center*) Microfat (lipoaspirate harvested with a 3-mm multiport cannula). (*Below*) Nanofat (lipoaspirate harvested with a 3-mm multiport cannula followed by an emulsification procedure). Macrofat (*above*) and microfat (*center*) show good adipocyte viability and adipose tissue structure in contrast with the nanofat (*below*), where no adipocytes and no normal adipose tissue structure are visible.

300 μ l of magnetic-activated cell-sorting rinse buffer. The cell suspension was passed through the magnetic-activated cell-sorting column (Miltenyi

Table 1. Results of the Cell Count from the Three Single Fat Samples

	SVF*	CD34 ⁺ Fraction*	CD34 ⁺ /SVF Ratio (%)
Macrofat (standard cannula)	3,075,000	200,000	6.5
Microfat (multiperforated cannula)	2,360,000	105,000	4.5
Nanofat (multiperforated cannula plus emulsification)	1,975,000	100,000	5.1

SVF, stromal vascular fraction.

*No. of cells per 100 ml of lipoaspirate.

Biotec) twice. The CD34⁺ fraction was collected, counted, and cultivated in a T25 Falcon flask in standard medium.

Stem Cell Differentiation

The adherent stromal vascular fraction cells and the CD34⁺ cells were seeded onto Thermanox

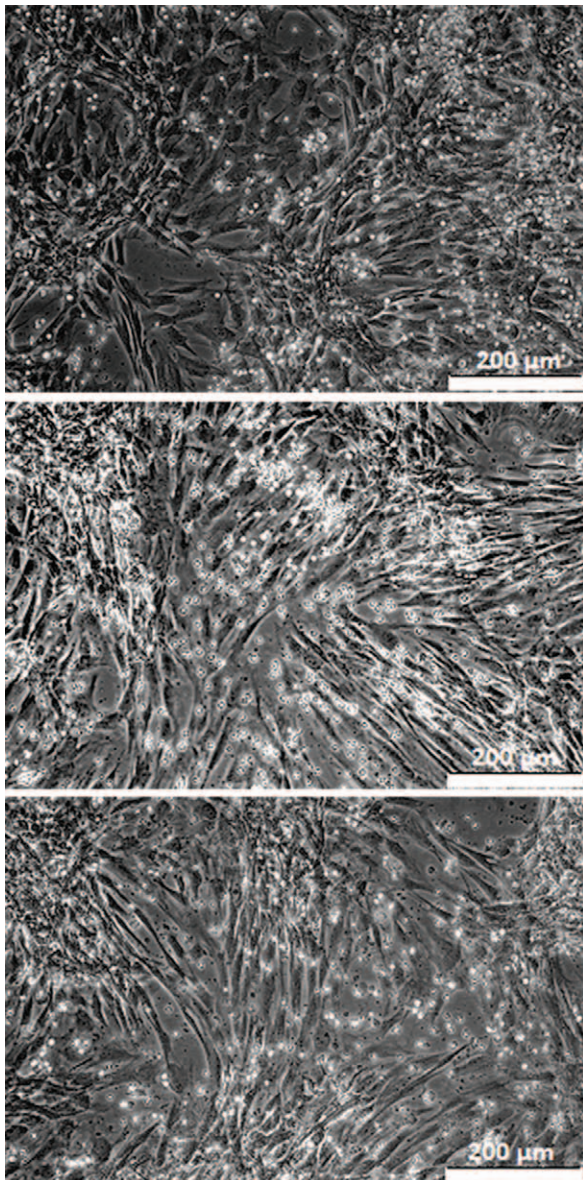


Fig. 3. Phase-contrast microscopic images of the stem cell cultures derived from the stromal vascular fraction after 7 days. (Above) Stem cell culture derived from the macrofat. (Center) Stem cell culture derived from the microfat. (Below) Stem cell culture derived from the nanofat. Note a typical fibroblastic morphology of the proliferating cells in the three samples.

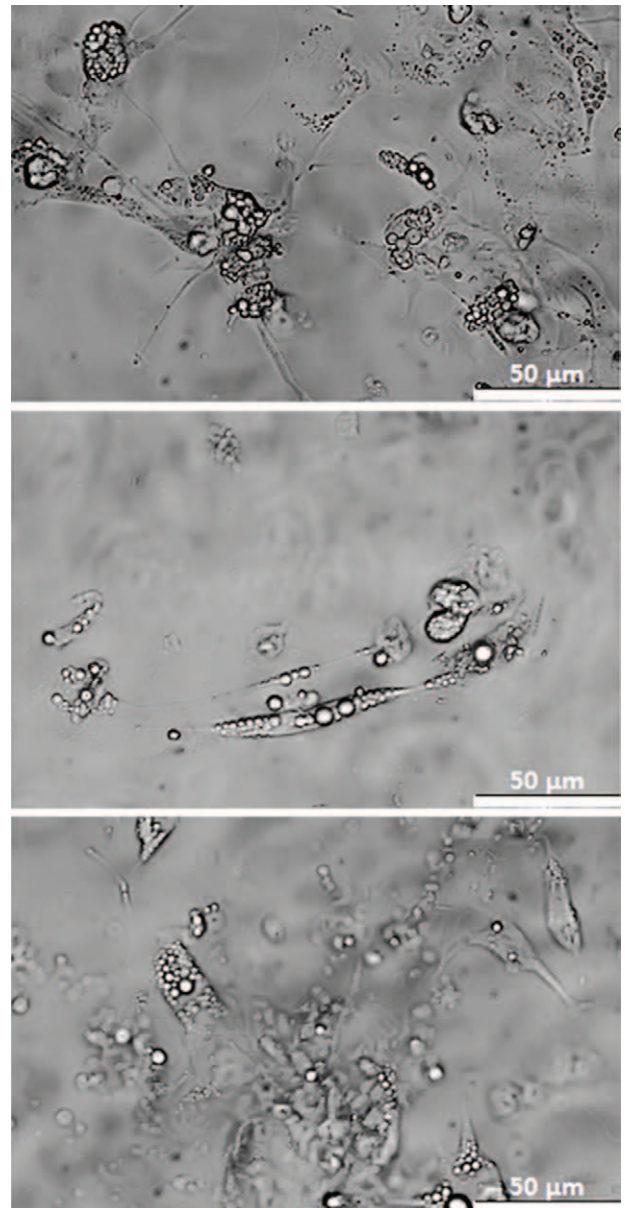


Fig. 4. Phase contrast microscopic images of stem cells derived from the three lipoaspirates and cultured in adipogenic culture medium for 10 days. Stem cells derived from the stromal vascular fraction from macrofat (above), microfat (center), and nanofat (below). Note the appearance of fat vacuoles in all 3 samples.

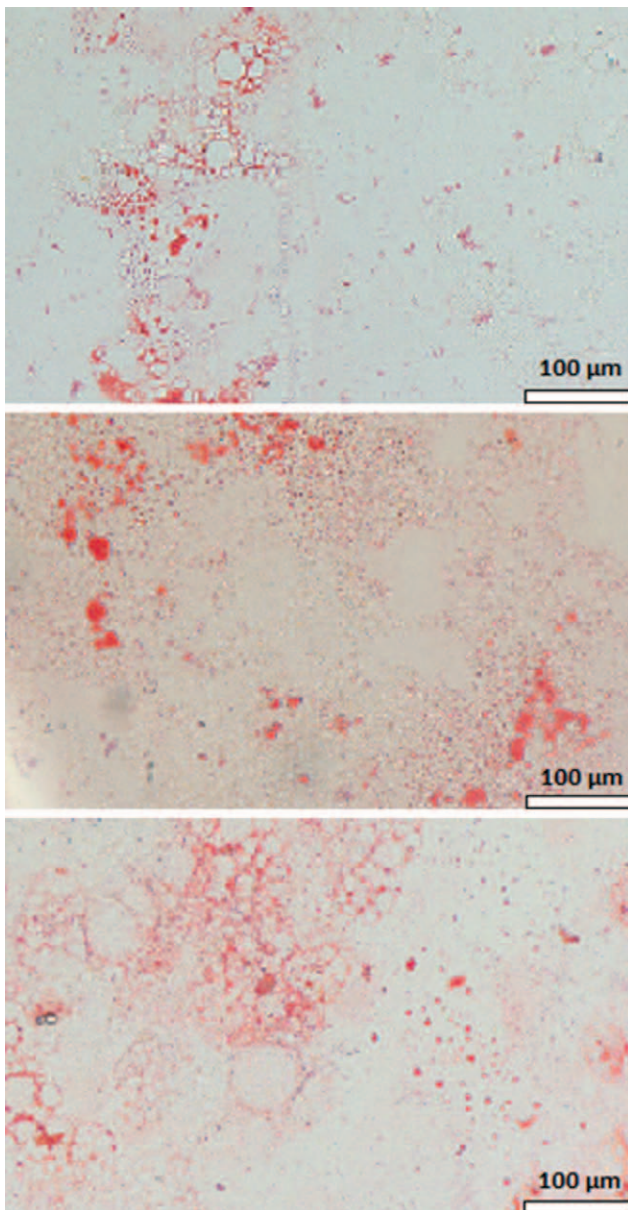


Fig. 5. Light microscopic images (oil red O staining) of stem cells derived from the three lipoaspirates and cultured in adipogenic culture medium for 10 to 28 days. Stem cells derived from the stromal vascular fraction (*above* and *center*) or the CD34⁺ (*below*) fraction from macrofat (*above*), microfat (*center*), and nanofat (*below*).

coverslips (Nunc, Roskilde, Germany) at a concentration of 40,000 cells per well in a 24-well plate (Greiner Bio-One, Gloucestershire, United Kingdom) and cultured in standard medium. After confluence, standard medium was replaced by adipogenic differentiation medium (Stempro Adipogenic Medium; Invitrogen) and cultured for 14 to 21 days.

Adipocyte differentiation was noticed by the intracellular accumulation of lipid droplets. Lipid

droplets were evaluated by phase-contrast microscopy and verified using light microscopy after oil red O staining.

RESULTS

Adipocyte Viability

After calcein AM/propidium iodide staining, the three different lipoaspirate samples were evaluated on their adipose tissue quality and adipocyte viability. In the macrofat (Fig. 2, *above*) and microfat (Fig. 2, *center*), adipose tissue with a normal histologic structure could be visualized. The adipocytes were viable (green), and only a very few dead cells could be observed. This was in high contrast with the nanofat (Fig. 2, *below*), where the adipose tissue structure was completely disturbed and replaced by an oily emulsion. No viable adipocytes were noticed in the nanofat.

Stem Cell Isolation and Culture

After isolation of the stromal vascular fraction and the CD34⁺ subpopulation from the three lipoaspirates, a cell count was performed. The number of viable stem cells derived from the stromal vascular fraction ranged from 1.9 to 3.0 × 10⁶ cells/100 ml lipoaspirate, independent of the processing method of the adipose tissue. The number of CD34⁺ cells in this stromal vascular fraction ranged from 0.1 to 0.2 × 10⁶ cells/100 ml lipoaspirate, resulting in a 4.5 to 6.5 percent CD34⁺–stromal vascular fraction ratio (Table 1).

The stromal vascular fraction and CD34⁺ cells were cultured in standard medium. Adherent cells in both stromal vascular fraction and CD34⁺ fractions formed monolayers and presented a fibroblastic morphology. No differences in cell cultures were noticed between the three different lipoaspirate samples (Fig. 3).

Stem Cell Differentiation

To demonstrate the stem cell nature of the stromal vascular fraction and CD34⁺ fraction, cells were plated in control or adipogenic medium for differentiation into mature adipocytes. After 10 days of culture in adipogenic medium, phase contrast microscopic evaluation showed the presence of spherical cells containing lipid vacuoles, indicating differentiation into the adipogenic lineage. No differences in quality and quantity of adipocytes between the different lipoaspirate samples were noticed (Fig. 4). Stem cells cultured in standard medium remained fibroblast-like. Light microscopy after oil red O staining confirmed the presence of

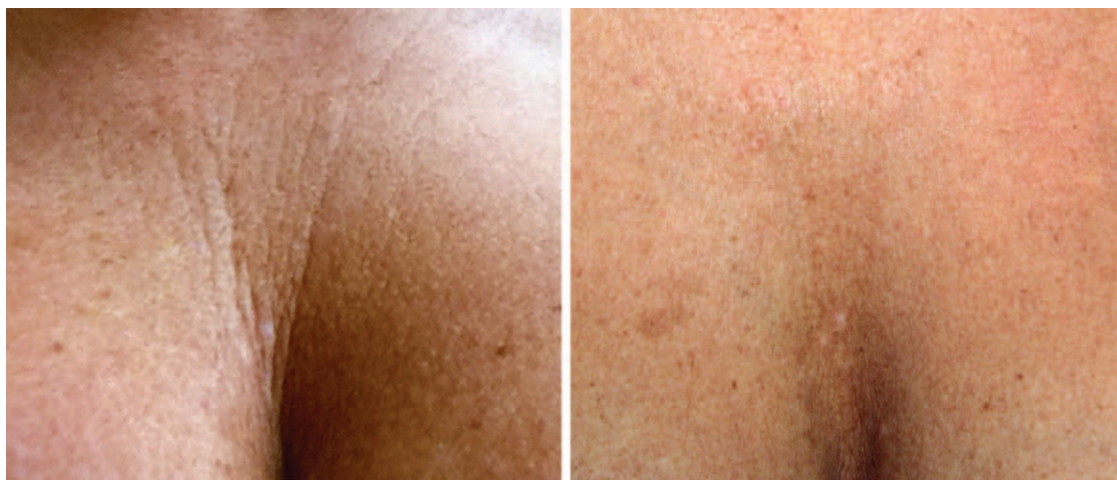

Fig. 6. Case 1. (Left) Sun-damaged skin in a 41-year-old woman at the décolletage with fan-shaped vertical rhytides. (Right) Three months after injection of 6 cc of microfat in the rhytides and 12 cc of nanofat in a superficial subdermal level of the whole décolleté area. Note the complete disappearance of the actinic aspect of the skin and the adequate correction of the rhytides.

large adipocytes, independent of the lipoaspirate processing method (Fig. 5).

Clinical Results

Between May of 2010 and September of 2012, nanofat grafting was performed in 67 cases. Intra-dermal injection was performed with a 27-gauge needle. The endpoint of injection was until a yellowish discoloration of the skin appeared. This discoloration usually disappeared a few hours after the injection. The clinical results gradually improved over time and were maximal from 4 to 6 months postoperatively. There were no important complications seen in this series. No infections, fat cysts, granulomas, or other unwanted side effects were observed. In injections of larger areas such as the décolletage or the face, there was a temporary erythema of the injected area that lasted for 1.5 to 2 days.

CASE REPORTS

Case 1

A 41-year-old woman complained about fan-shaped vertical rhytides and sun-damaged skin in the décolleté area (Fig. 6). The rhytides were injected intradermally in a longitudinal fashion with 6 cc of microfat using a 23-gauge needle. Injection was performed until a slight overcorrection was seen. Next, the whole triangular surface of the décolleté area was injected at a superficial subdermal level with 12 cc of nanofat using a 27-gauge needle in repeated fan-shaped patterns. The first few weeks after injection, the treated area appeared overcorrected but gradually normalized toward the result seen at 3 months (Fig. 6).

Case 2

A 33-year-old woman sought improvement of the aesthetics of her lower eyelids. She presented with a moderate bulging of the lower eyelid fat compartments with a marked eyelid-check junction. The skin of the lower eyelid was heavily pigmented with an extension of this pigmentation along the nasojugal groove (Fig. 7, left). The patient mentioned that the discoloration had been present since childhood. A lower eyelid blepharoplasty with fat redraping over the lower and lateral orbital rim was proposed

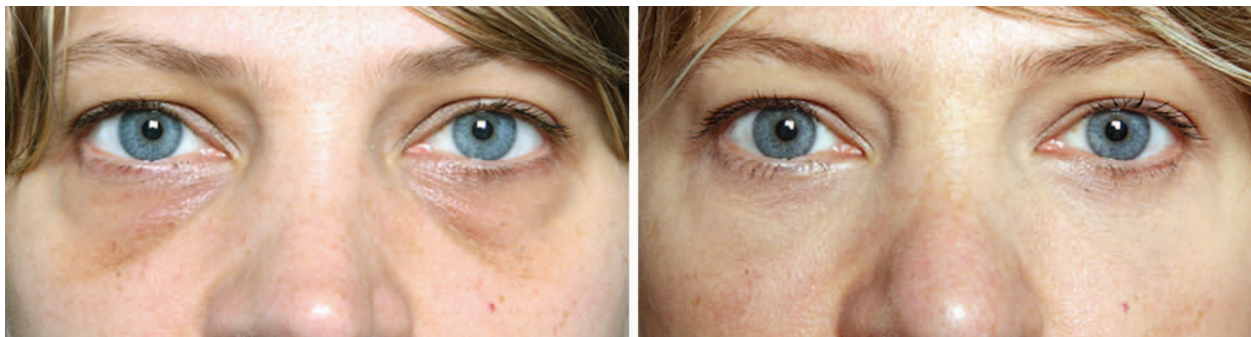

Fig. 7. Case 2. (Left) A 33-year-old woman with lower eyelid blepharochalasis and dark coloration of the lower eyelid skin extending into the nasojugal groove. (Right) Seven months after fat redraping, blepharoplasty, and intradermal injection of 1.6 cc nanofat in the lower eyelid and pigmented nasojugal groove.

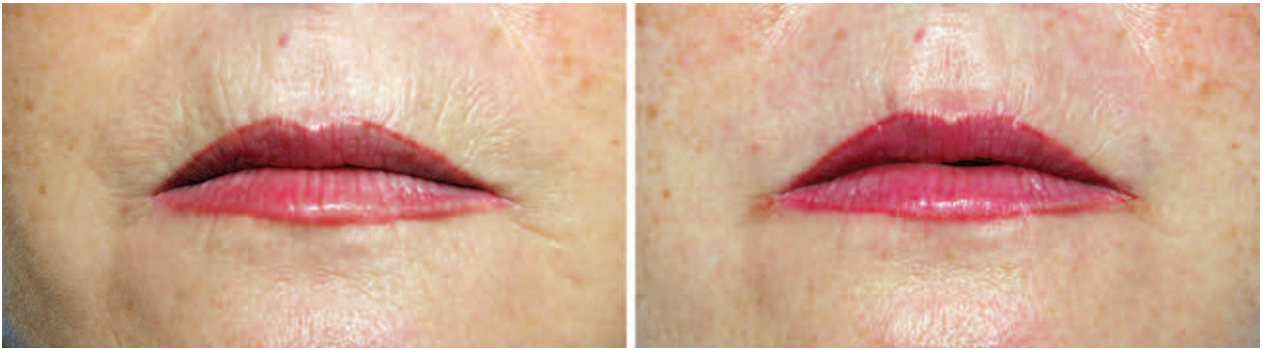


Fig. 8. Case 3. (Left) A 61-year-old woman with perioral rhytides and who refused to undergo any laser resurfacing procedure. (Right) Result 7 months after injection of 4 cc of intradermal microfat graft into the rhytides, accompanied by intradermal injection of 6 cc of nanofat in the perioral skin. Note the better skin quality in the treated area.

together with intradermal infiltration of nanofat to improve the pigmentation of the skin. The operation was performed under local anesthesia combined with intramuscular midazolam sedation. A classical infraciliary incision was carried out for the fat redraping and blepharoplasty procedure. After completion of the blepharoplasty, the eyelid skin and the nasojugal groove were injected intradermally with 1.6 cc of nanofat per side. At the end of the injections, the whole lower eyelid was colored yellowish like a giant xanthelasma. The whitish discoloration disappeared after 1 month. The lower eyelid skin remained erythematous for 3 months, followed by a gradual lightening of the skin (Fig. 7, right).

Case 3

A 61-year-old woman consulted for perioral rejuvenation, mainly the correction of the vertical rhytides of the upper and lower lips. She refused to have any laser resurfacing procedure (Fig. 8).

Microfat grafting at the rhytides of the lip together with nanofat grafting of the whole perioral region and cheeks were performed. Then, 4 cc of microfat was injected with a 23-gauge needle into the rhytides (sharp needle intradermal fat grafting technique), and 6 cc of nanofat was used for intradermal injection into the skin of the upper and lower lips and in both cheek areas.

DISCUSSION

For microfat grafting, usually performed in the facial area, blunt injection cannulas ranging from 0.7 to 0.9 mm are used with very good results. To provide a smooth injection through these fine cannulas, the fat particles need to be sufficiently small. If the fat particles are too large, passage through the injection cannula would be difficult. A disrupted injection will follow, which may result in an unequal lipofilling with irregular fat deposits.

To provide a lipoaspirate with smaller particles for microfat grafting procedures at the lower eyelid, Trepsat used a multiperforated harvesting cannula of 2 mm with 1-mm side holes and 19-gauge injection cannulas. A multiperforated liposuction cannula 3 mm in diameter with 2-mm side holes was used to harvest fat for injection of

other parts of the face.¹² Nguyen et al. described the use of a similar multiperforated harvesting cannula with side holes of 1 mm.¹⁴ Coleman and Mazzola reported the use of injection cannulas up to 22 gauge.¹³ Nguyen et al. applied blunt injection 25-gauge cannulas in a mouse model and mentioned the use of blunt 21- or 23-gauge cannulas for fat grafting in clinical cases.¹⁴

To ensure a smooth fat injection through 27-gauge sharp needles, the aspirated fat has to be processed mechanically to provide a liquid fat emulsion, which we call nanofat. A yield of 1 ml of nanofat per 10 ml of lipoaspirate can be expected using a nanofat processing procedure as described above.

Our initial goal of local injections with nanofat using 27-gauge needles was to use it as filler for superficial rhytides. Because of the reduced number of viable adipocytes in the emulsified fat, the filling capacity of nanofat is obviously very limited. After noting a clear skin rejuvenation effect in our clinical cases, we started to use nanofat to improve skin quality.

Other studies used lipofilling as an instrument for skin regenerative purposes such as treatment of radiotherapy ulcers or scars.^{17–19} One study reported a clear and statistically significant improvement in dermal elasticity after injection of facial scars in 14 patients.¹⁸ The mechanism for this regenerative effect on damaged skin remains unknown. Improved elasticity is presumably a consequence of increased collagen and elastin synthesis and remodeling. These effects are most likely triggered by stem cells rather than by grafted adipocytes. Moreover, the nanofat sample analysis revealed that adipocytes were destroyed during the emulsification process.

To isolate stem cells, the stromal vascular fraction has to be separated from the adipocytes. The stromal vascular fraction contains different types of cells, such as endothelial cells,

monocytes, macrophages, granulocytes, and lymphocytes. The stromal vascular fraction also includes a substantial amount of mesenchymal stem cells (adipose-derived stem cells). These multipotent stem cells have the ability to adhere to plastic culture plates and to form fibroblast-like colonies. Likewise, stem cells can be isolated by culturing the adherent stromal vascular fraction cells. It is remarkable that these multipotent stem cells are richly present in fat tissue, in contrast to bone marrow or other sources of multipotent mesenchymal stem cells.²⁰ Adipose-derived stem cells have an extensive proliferative capacity and the ability to differentiate into the mesoderm, ectoderm, and endoderm lineages.^{21–24}

It has been demonstrated that cells with a CD34⁺ phenotype represent a cell population with a great stem cell proliferative capacity.^{21,25–32} In this study, stem cells were isolated in two ways. First, cells from the stromal vascular fraction were selected on their adherence to the plastic plate. These adherent cells were further cultured. Second, as a control experiment, the CD34⁺ subpopulation was isolated from the stromal vascular fraction and cultured as well.

The lipoaspirate viability evaluation shows that the nanofat sample has lost the normal fat tissue structure and that adipocytes are eliminated during nanofat processing. However, a large number of good quality mesenchymal stem cells are still present in the nanofat sample.

Classic fat grafting is mostly used to build up large volumes, especially in breast reconstructive cases. In those cases, it is crucial to preserve as many viable adipocytes as possible. Nanofat does not have the capacity to build up a significant fat volume. Consequently, nanofat is evidently not suitable for these indications. In fact, because of the lack of adipocytes, the volumetric effect of nanofat is obviously very limited. Therefore, the indications for nanofat injection are different when compared with microfat grafting. Usually, nanofat grafting is combined with other modalities of microfat grafting such as sharp needle intradermal fat grafting to obtain a soft-tissue filling effect, where the nanofat is layered more fanwise in an intradermal level to enhance the skin quality. In our experience, as opposed to microfat, the effect of nanofat usually appears with a delay of 4 weeks to 3 months. In the case where dark circles were treated, the beneficiary effect was preceded by a rather prolonged erythematous phase, which most likely is attributable to the soft-tissue rearrangement.

In fact, it may be questioned whether a nanofat transfer actually is a “fat grafting” procedure, as adipocytes did not survive the emulsification process. The major effect of nanofat injection is probably a stem cell activity. Likewise, nanofat injection might rather be considered as an *in vivo* tissue-engineering process. It might be logical to discard the dead adipocyte fraction from the nanofat and to inject the purified stromal vascular fraction only. However, isolating the stromal vascular fraction out of the nanofat before injection in routine clinical cases would be time consuming, complicated, and expensive. Besides, it requires specific laboratory equipment and experience. Moreover, it is known that apoptotic cells release cytokines and attract macrophages that induce growth factors and play an important role in regeneration of the damaged tissue.³³ Thus, co-injection of fragmented adipocytes might have a stimulating effect on stem cell differentiation and tissue regeneration.

This is the first report of a new fat grafting technique that we have been using since May of 2010. Clinical assessment was performed by our observations and preoperative and postoperative photographs. No other objective measurements or objective skin quality tests have been performed. In addition to the three clinical cases, we present the results of our laboratory pilot study comparing three fat samples. More fat samples have to be analyzed to determine the content of the nanofat in a statistically significant way. Furthermore, histologic evidence of the nanofat effect is not present yet. Further studies will have to determine whether the clinical observations can be correlated with preoperative and postoperative histologic analysis. These studies are in progress.

CONCLUSIONS

Nanofat injection may become another concept in the lipofilling area. In this study, it seems that stem cells are responsible for the clinical results seen after nanofat injections. Clinically, nanofat appears suitable for skin rejuvenation procedures. Further studies have to be performed to find statistically significant evidence for the nanofat effect.

Geert Peeters, M.D.

Department of Plastic Surgery
University Hospital of Brussels
Laarbeeklaan 101
1090 Brussels, Belgium
gpeetersg@gmail.com

REFERENCES

1. Neuber G. Fetttransplantation. *Verh Dtsch Ges Chir.* 1893;22:66.
2. Illouz YG. Body contouring by lipolysis: A 5-year experience with over 3000 cases. *Plast Reconstr Surg.* 1983;72:591–597.
3. Coleman SR. Long-term survival of fat transplants: Controlled demonstrations. *Aesthetic Plast Surg.* 1995;19:421–425.
4. Coleman SR. Structural fat grafts: The ideal filler? *Clin Plast Surg.* 2001;28:111–119.
5. Zuk PA, Zhu M, Mizuno H, et al. Multilineage cells from human adipose tissue: Implications for cell-based therapies. *Tissue Eng.* 2001;7:211–228.
6. Okura H, Saga A, Soeda M, et al. Intracoronary artery transplantation of cardiomyoblast-like cells from human adipose tissue-derived multi-lineage progenitor cells improve left ventricular dysfunction and survival in a swine model of chronic myocardial infarction. *Biochem Biophys Res Commun.* 2012;425:859–865.
7. Fawzy El-Sayed KM, Dörfer C, Fändrich F, et al. Adult mesenchymal stem cells explored in the dental field. *Adv Biochem Eng Biotechnol.* E-published ahead of print September 1, 2012.
8. Oh JS, Park IS, Kim KN, Yoon do H, Kim SH, Ha Y. Transplantation of an adipose stem cell cluster in a spinal cord injury. *Neuroreport* 2012;23:277–282.
9. Puissant B, Barreau C, Bourin P, et al. Immunomodulatory effect of human adipose tissue-derived adult stem cells: Comparison with bone marrow mesenchymal stem cells. *Br J Haematol.* 2005;129:118–129.
10. Yoo KH, Jang IK, Lee MW, et al. Comparison of immunomodulatory properties of mesenchymal stem cells derived from adult human tissues. *Cell Immunol.* 2009;259:150–156.
11. Zhou B, Yuan J, Zhou Y, et al. Administering human adipose-derived mesenchymal stem cells to prevent and treat experimental arthritis. *Clin Immunol.* 2011;141:328–337.
12. Trepsat F. Midface reshaping with micro-fat grafting (in French). *Ann Chir Plast Esthet.* 2009;54:435–443.
13. Coleman SR, Mazzola RF. *Fat Injection: From Filling to Regeneration.* St. Louis: Quality Medical; 2009.
14. Nguyen PS, Desouches C, Gay AM, Hautier A, Magalon G. Development of micro-injection as an innovative autologous fat graft technique: The use of adipose tissue as dermal filler. *J Plast Reconstr Aesthet Surg.* 2012;65:1692–1699.
15. Dasiou-Plakida D. Fat injections for facial rejuvenation: 17 years experience in 1720 patients. *J Cosmet Dermatol.* 2003;2:119–125.
16. Zeltzer AA, Tonnard PL, Verpaele AM. Sharp-needle intradermal fat grafting (SNIF). *Aesthet Surg J.* 2012;32:554–561.
17. Rigotti G, Marchi A, Galiè M, et al. Clinical treatment of radiotherapy tissue damage by lipoaspirate transplant: A healing process mediated by adipose-derived adult stem cells. *Plast Reconstr Surg.* 2007;119:1409–1422; discussion 1423.
18. Sardesai MG, Moore CC. Quantitative and qualitative dermal change with microfat grafting of facial scars. *Otolaryngol Head Neck Surg.* 2007;137:868–872.
19. Akita S, Yoshimoto H, Ohtsuru A, Hirano A, Yamashita S. Autologous adipose-derived regenerative cells are effective for chronic intractable radiation injuries. *Radiat Prot Dosimetry* 2012;151:656–660.
20. Zhu X, Du J, Liu G. The comparison of multilineage differentiation of bone marrow and adipose-derived mesenchymal stem cells. *Clin Lab.* 2012;58:897–903.
21. Traktuev DO, Merfeld-Clauss S, Li J, et al. A population of multipotent CD34-positive adipose stromal cells share pericyte and mesenchymal surface markers, reside in a periendothelial location, and stabilize endothelial networks. *Circ Res.* 2008;102:77–85.
22. Brzoska M, Geiger H, Gauer S, Baer P. Epithelial differentiation of human adipose tissue-derived adult stem cells. *Biochem Biophys Res Commun.* 2005;330:142–150.
23. Cao Y, Sun Z, Liao L, Meng Y, Han Q, Zhao RC. Human adipose tissue-derived stem cells differentiate into endothelial cells in vitro and improve postnatal neovascularization in vivo. *Biochem Biophys Res Commun.* 2005;332:370–379.
24. Declercq HA, De Caluwé T, Krysko O, Bachert C, Cornelissen MJ. Bone grafts engineered from human adipose-derived stem cells in dynamic 3D-environments. *Biomaterials* 2013;34:1004–1017.
25. Boquest AC, Shahdadfar A, Frønsdal K, et al. Isolation and transcription profiling of purified uncultured human stromal stem cells: Alteration of gene expression after in vitro cell culture. *Mol Biol Cell* 2005;16:1131–1141.
26. Boquest AC, Shahdadfar A, Brinchmann JE, Collas P. Isolation of stromal stem cells from human adipose tissue. *Methods Mol Biol.* 2006;325:35–46.
27. Bailey AM, Kapur S, Katz AJ. Characterization of adipose-derived stem cells: An update. *Curr Stem Cell Res Ther.* 2010;5:95–102.
28. Suga H, Matsumoto D, Eto H, et al. Functional implications of CD34 expression in human adipose-derived stem/progenitor cells. *Stem Cells Dev.* 2009;18:1201–1210.
29. Gronthos S, Franklin DM, Leddy HA, Robey PG, Storms RW, Gimble JM. Surface protein characterization of human adipose tissue-derived stromal cells. *J Cell Physiol.* 2001;189:54–63.
30. Folgiero V, Migliano E, Tedesco M, et al. Purification and characterization of adipose-derived stem cells from patients with lipoaspirate transplant. *Cell Transplant.* 2010;19:1225–1235.
31. Deans RJ, Moseley AB. Mesenchymal stem cells: Biology and potential clinical uses. *Exp Hematol.* 2000;28:875–884.
32. Lin CS, Ning H, Lin G, Lue TF. Is CD34 truly a negative marker for mesenchymal stromal cells? *Cytotherapy* 2012;14:1159–1163.
33. Mahdavian Delavary B, van der Veer WM, van Egmond M, Niessen FB, Beelen RH. Macrophages in skin injury and repair. *Immunobiology* 2011;216:753–762.