

## Thermistor-Controlled Subdermal Skin Tightening for the Aging Face: Clinical Outcomes and Efficacy

Akshay Sanan, MD; Nikolaus Hjelm, MD ; Patrick Tassone, MD ; Howard Krein, MD, PhD;  
Ryan N. Heffelfinger, MD

**Objective:** Patients are increasingly seeking nonsurgical treatment for the aging face. The purpose of this study was to evaluate the clinical efficacy and outcomes of a thermistor-controlled subdermal skin tightening device (ThermiTight) as a treatment modality for the aging face.

**Methods:** A retrospective analysis of 12 patients was completed on patients having undergone ThermiTight for midface and neck skin tightening. Only five patients had a greater than 1 year follow-up and were included in the study. Two blinded reviewers assessed photographs taken pre-procedure and 1 year post-procedure using a standardized skin laxity scale. Patient charts were reviewed to assess for complications up to 12 months post-treatment.

**Results:** The mean age of included patients was 57 years, and all five patients were female. One (20%) patient treated with ThermiTight was also treated with injectables (Botox, Juvéderm) simultaneously. One (20%) patient developed a wound complication. One (20%) patient complained of incisional site pain at her first postoperative visit that subsequently self-resolved. On a five-point scale to assess facial skin laxity, there was an average improved score of 0.85 per patient ( $P < .001$ ) at one year post-procedure. Two blinded reviewers correctly categorized photographs as either being “baseline” or “post-procedure” 100% of the time. There was no significant difference between the skin laxity scores by the blinded reviewers ( $P = .05$ ).

**Conclusion:** ThermiTight is a new technology used for nonsurgical treatment of the aging face. Long-term outcomes demonstrate the safety and efficacy of the procedure. Complications are rare, but possible, in the use of ThermiTight.

**Level of Evidence:** 3

**Key Words:** Thermistor, ThermiTight, aging face, skin laxity, injectable, aesthetic surgery.

### INTRODUCTION

Facial soft tissues undergo age-related changes in volume, shape, and position. Considerations for the cause of skin aging and loss of quality include, but are not limited to, loss of subcutaneous fat, prominence of platysmal banding, jowling along the mandibular border, and excessive skin laxity resulting from a decline in collagen and elastin.<sup>1</sup>

Rhytidectomy was introduced in the early 1900s as the first face-lift procedure. With advances in technique, subfascial dissection of the anatomical superficial musculoaponeurotic system (SMAS) became widespread.<sup>2</sup> Despite the marked efficacy of this procedure, concerns regarding the excisional nature of this surgery and visible scars limited its popularity.<sup>3</sup> In response to this, a number of less-invasive treatments ranging from botulinum toxin injections to tissue fillers were introduced.<sup>4</sup> Soft tissue fillers are designed to address fat atrophy. Soft tissue fillers

and neurotoxin injection produced a paradigm shift toward office-based techniques.<sup>5</sup>

Although these injection procedures are relatively easy to perform and effective in treating aging face, they are not suitable for skin laxity, nor do they remove abnormal fat deposits. A widely used noninvasive skin tightening solution has been transcutaneous thermogenesis, which is achieved using ultrasound, radiofrequency, or light. These techniques exert a thermo-mechanical effect to induce neocollagenesis, denaturation of multi-chain collagen cross-links, activation of wound healing pathways, collagen contraction and increased collagen fibril size.<sup>6,7</sup>

A major disadvantage of transcutaneous thermogenesis is the poor penetration of energy into deeper dermal and subdermal tissues, which can result in uneven contouring and scar formation.<sup>8</sup> Another potential drawback to transcutaneous thermogenesis technologies is that the temperature required to cause an epidermal burn is lower than the temperature required to remodel the subdermal layers. A newly emerging approach that provides precise and controlled subdermal heating is thermistor-controlled subdermal skin tightening (ThermiTight, ThermiAesthetics, Southlake, TX). This approach uses a percutaneous treatment probe to administer radiofrequency directly to dermal and subdermal tissue. Subdermal temperatures are monitored and controlled by a thermistor integrated within the thermocoupled handpiece.<sup>9</sup> Concurrently, epidermal temperatures are monitored using an infrared camera system. Therefore, both subdermal and

This is an open access article under the terms of the Creative Commons Attribution-NonCommercial-NoDerivs License, which permits use and distribution in any medium, provided the original work is properly cited, the use is non-commercial and no modifications or adaptations are made.

From the Department of Otolaryngology–Head and Neck Surgery (A.S., N.H., P.T., H.K., R.N.H.), Thomas Jefferson University Hospital, Philadelphia, Pennsylvania, U.S.A.

Send correspondence to Nikolaus Hjelm, MD, Thomas Jefferson University Hospital, Department of Otolaryngology–Head and Neck Surgery, 925 Chestnut Street, 6th Floor, Philadelphia, PA 19107. Email: nikolaus.hjelm@jefferson.edu

DOI: 10.1002/liv.2.228

dermal collagenous tissue reaches therapeutic temperature thresholds necessary for collagen remodeling. With this in mind, we sought to evaluate the outcomes and clinical efficacy of ThermiTight for reversing neck and lower face skin laxity.

## METHODS

Following institutional review board (IRB) approval, we retrospectively reviewed 12 patients undergoing ThermiTight treatment to rejuvenate neck and lower face skin under local anesthesia. Only five patients had a greater than 1 year follow-up and were included in the study. Treated sites included the submentum and jowls. All participants provided verbal and written consent of risks, benefits, and permission for photographic documentation. Frontal and profile views with patients in the Frankford horizontal against a contrasting background were taken at a pre-procedure visit, and again following ThermiTight intervention.

Two blinded reviewers assessed photographs taken at baseline and 12 months post-procedure. Reviewers were presented with both photographs at the same time and asked to label each photograph as either the “baseline” or “post-procedure” image. Blinded grading was performed using a quantitative five-point grading scale to assess changes in skin laxity (Table I)<sup>10</sup>; this scale rates skin laxity from 0 (no significant skin laxity) to 4 (severe skin laxity), with half-point ratings throughout (eg, 1.0, 1.5, 2.0, 2.5).

Patient charts were reviewed for the 12 months following ThermiTight treatment to evaluate for any complications. Complications included infection, wound breakdown, patient dissatisfaction, or uneven contour.

Inclusion criteria for ThermiTight treatment were: good health and mild to severe skin laxity. Exclusion criteria were: any injection history such as silicone, fat, or collagen; bleeding or coagulation disorder; history of a hypertrophic scar or keloid; compromised immune system; history of impaired wound healing; or collagen vascular disease. Patients were required to be available for post-treatment follow-up evaluations.

TABLE I.  
Skin Laxity Severity Scale.

Grade	Descriptive Parameter	Laxity
0	None	None
1	Mild	Localized to NL folds
1.5	Mild	Localized, NL and early ML folds
2	Moderate	Localized, NL/ML folds, early jowls, early SM
2.5	Moderate	Localized, prominent NL/ML folds, jowls, and SM
3	Advanced	Prominent NL/ML folds, jowls and SM, early neck strands
3.5	Advanced	Deep NL/ML folds, prominent jowls and SM, prominent neck strands
4	Severe	Marked NL/ML folds, jowls and SM, neck redundancy and strands

NL = Nasolabial; ML = Melolabial, SM = Submental/Submandibular

ThermiTight treatments were performed by the two senior authors (HK, RH). Before treatment, the patient's skin was cleaned with betadine. Patients received a local injection of 1:100,000 epinephrine mixed with 1% lidocaine at the procedure site. An additional local anesthetic (Tumescent solution) was used in the submental and lateral neck regions. A blunt 10 cm long, 18-gauge percutaneous temperature probe was inserted at an angle nearly parallel to the dermal plane. The distal end of the treatment probe administered the radiofrequency, which possessed a temperature sensor that initiated an automatic feedback loop to maintain subdermal tissue temperature (ThermiRF). The ThermiTight probe temperature was set between 50 to 60 °C and was maintained using the thermistor integrated electrode. Temperature monitoring was conducted using a forward looking infrared radiometer (FLIR) imaging system. The FLIR system allows for radiometric IR-video streaming with thermal monitoring of the entire physical field rather than a single spot. The procedure was performed as previously described by Key.<sup>11</sup>

The treatment design involved a crisscross pattern, with the treatment probe moving medially from the lateral entry point and laterally from the middle entry point. The clinical endpoint was an epidermal temperature of 42 °C.

## Statistical Analysis

Pre- and post-procedure skin laxity scores were compared by paired Student's t-test. Changes in skin laxity scores were also compared between reviewers to detect any difference between reviewer scores; these differences were plotted on a histogram. Statistical analyses were performed using R statistics package version 3.3.1 (R Foundation, Vienna, Austria). Differences were considered significant at *P*-value <.05.

## RESULTS

### Safety

One patient developed a facial abscess after ThermiTight, which required an incision and drainage and overnight admission for intravenous antibiotics. One patient complained of incisional site pain at their first postoperative visit, which resolved spontaneously by the patient's subsequent appointment. There were no complications of wound breakdown, surface irregularities, or numbness. Patients could return to their normal activity immediately after treatment.

### Efficacy

Average skin laxity score as assessed by two blinded reviewers improved from 2.75 pre-procedure to 1.90 post-procedure, an average change of 0.85 points (*P* < .001) (Table II) Highest average score improvement was 1.25 points, and lowest average score improvement was 0.5 points. One hundred percent of patients' post-procedure photos were rated as having improved skin laxity.

The two-blinded reviewers had improvement scores within one point of each other in 80% of patients, and had

N = 12	Baseline	Post-Procedure	Difference
<b>Mean +/- SD</b>	2.75 +/- 0.64	1.90 +/- 0.82	-0.85 (p < 0.001)

perfect agreement in 20% of cases (Fig. 1). No significant difference between reviewer assessments of change was detected by t-test ( $P = .06$ ).

Examples of clinical outcomes of patients after ThermiTight treatment are shown in Figs. 2 and 3. The patient in Fig. 2 is a 49-year-old female with images at baseline and 12 months post-procedure; she also had Botox injected to her forehead, glabella and crow's feet. Each blinded reviewer reported an improvement of 1.0 on the skin laxity severity scale. The patient in Fig. 3 is a 55-year-old female with images at baseline and three months post-procedure. Each blinded reviewer reported an improvement of 0.5 on the skin laxity severity scale.

## DISCUSSION

Skin laxity and abnormal fat accumulation are highlighted in the aging face and neck through the submental area, jowls, lateral nasolabial folds, lateral labio-mental folds, and lateral mental areas.<sup>12</sup> These changes lead to morphological disruption, resulting in an older appearance. ThermiTight is a new technology for lipolysis and contouring, which can cause neocollagenesis via radiofrequency energy applied directly to target tissues. Skin laxity is largely caused by changes in connective tissue including collagen, elastin, and ground substances. Collagen is a triple helix with chains held together by hydrogen bonds. Collagen molecules are organized as

fibrils, whose tensile properties are caused by intermolecular cross-links.<sup>13</sup>

When collagen is denatured by heat, the hydrogen bonds rupture, and the triple helices unwind, resulting in randomly coiled molecules. Although collagen fibers contract, certain heat-stable cross-links are maintained, and the elastic properties of the collagen increase. This heat-modified collagen undergoes remodeling associated with fibroplasia and new collagen synthesis.<sup>14</sup> Lin et al. noted that collagen fibers began to curve at 52 to 55 °C.<sup>13</sup> On the basis of these theories, we set the maximum temperature of 60 °C, which was measured by a micro-thermosensor inside the tip of the cannula. When the internal temperature was close to 60 °C, the epidermal temperature measured with an external infrared thermometer was set to a max of 42 °C.

ThermiTight is a monopolar RF device. In monopolar systems, current flows from an electrode placed in contact with the tissue to a grounding electrode positioned on the skin far from the other electrode.<sup>15</sup> Monopolar RF energy delivers heat deep enough to involve the fibrous septae of the fat layer. Key retrospectively analyzed 18 patients who were treated with ThermiTight in the under-chin/jowl area, abdomen, above the knees and buffalo hump and assessed for reliability of the FLIR system reporting temperature differences between the epidermal and dermal regions. He concluded the device consistently reported subsurface and epidermal temperatures accurately; of note, no adverse events were reported in his study.<sup>9</sup> One of the drawbacks to the ThermiTight device is that the device has no ability to suction fat.

One patient in our series had an adverse event: facial abscess after ThermiTight. To the authors' knowledge, this is the first reported ThermiTight complication. Interestingly, the patient was a 60-year-old female who 3 years prior underwent a facelift. Her postoperative

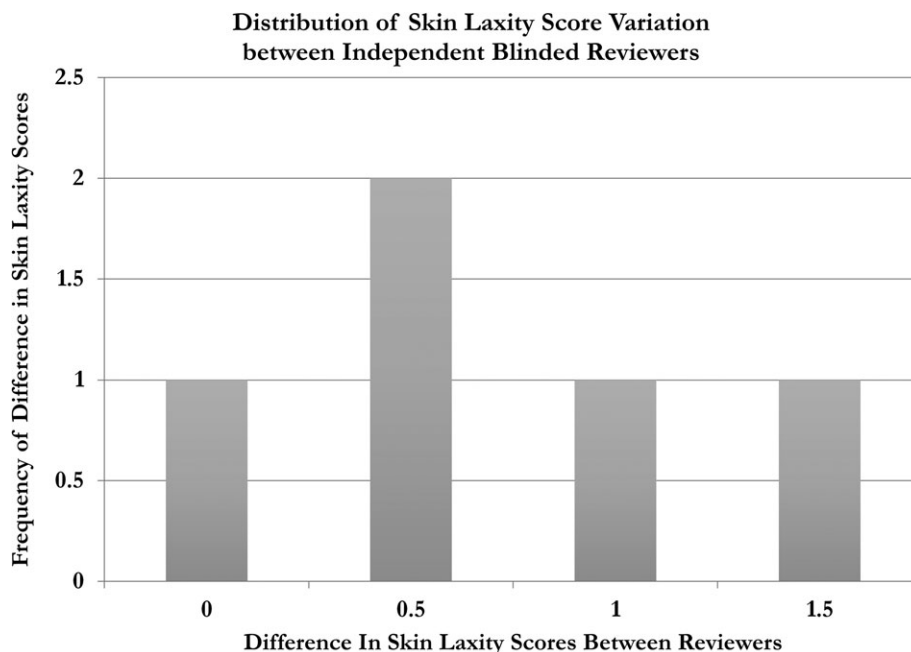


Fig. 1. Distribution of skin laxity score variation between independent blinded reviewers.

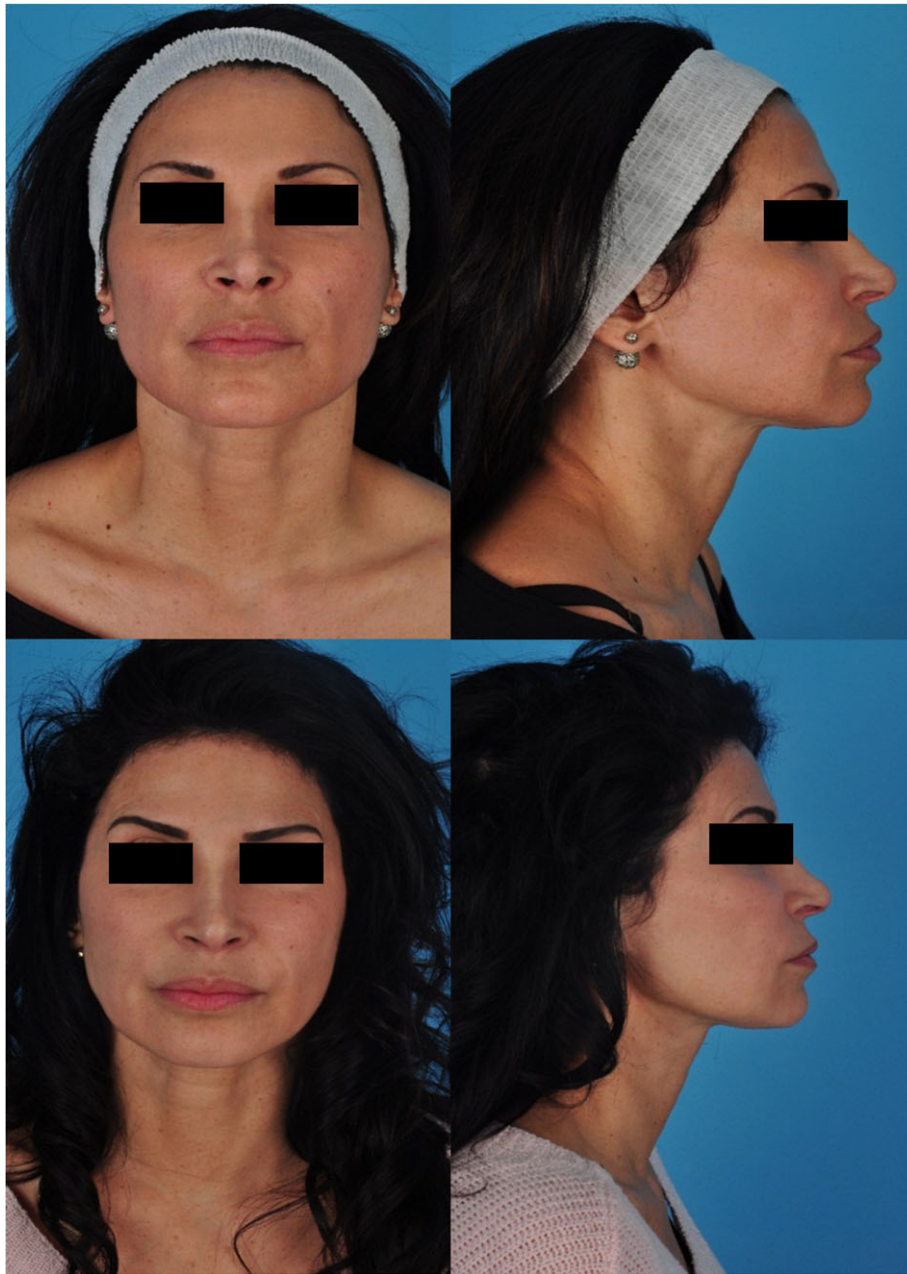

Fig. 2. Forty-nine-year-old female who underwent ThermiTight for submental skin laxity and jowling. Preoperative (A) and 12 months post-procedure (B) front and profile views.

course for the facelift was complicated by facial cellulitis. She did not have any underlying immunologic deficiency, diabetes, autoimmune disease, or wound healing history. She was seen at her first postoperative visit 6 days after ThermiTight treatment, admitted to the hospital and started on intravenous antibiotics. A CT scan demonstrated cellulitis of the left face without a drainable collection. She did not improve on intravenous antibiotics and a bedside incision and drainage was performed. Fifteen cc of pus was drained from the ThermiTight treatment site and cultures grew methicillin-resistant *Staphylococcus aureus* (MRSA). She was discharged home the following day with an oral antibiotic regimen. She did not have any other sequelae from treatment and subjectively was satisfied

with her result. Studies have suggested that heating subcutaneous tissue leads to increased oxygen tension which may increase bactericidal activity.<sup>16,17</sup> Therefore we believe that, despite our sterile technique as recommended by the World Health Organization, the micro-thermosensor or our subcutaneous tumescent injections seeded the patient's neck with MRSA.<sup>18</sup>

One patient complained of incisional site discomfort at her first postoperative visit. This self-resolved by the second postoperative visit. The patient was prescribed narcotic pain medication but counseled that she should transition to nonnarcotic analgesics as soon as possible.

In our experience, the use of a subsurface radio-frequency thermistor produced significant improvement

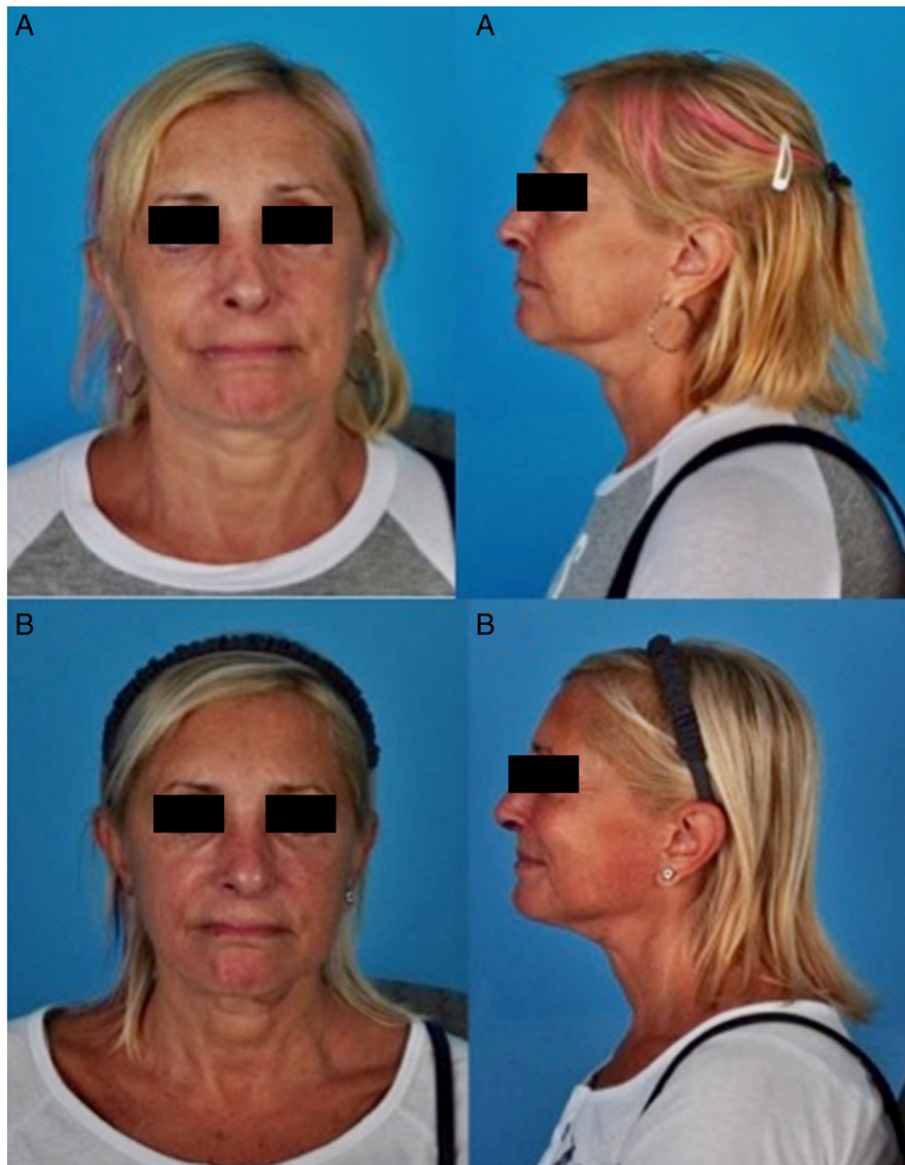

Fig. 3. Fifty-five-year-old female who underwent ThermiTight for submental skin laxity and jowling. Preoperative (A) and 12 months post-procedure (B) front and profile views.

for lower face and neck contouring in the aging face with a minimal side effect profile. Theoretically, an ideal subdermal skin tightening device should: 1) affect subdermal tissues without compromising the viability of the overlying skin-soft tissue envelope, 2) cause soft-tissue envelope contraction around the area of the treated tissue, 3) be safe to use on patients under local anesthesia, and 4) lead to minimal bruising and swelling, allowing for quick return to daily activities without significant downtime. ThermiTight fulfills all of these aforementioned criteria, and led to reliably improved skin laxity scores. The authors recommend ThermiTight for the aging face based on our long-term data. Limitations of this study are the retrospective design and small number of patients. Studies with larger sample sizes and follow-up periods are needed to assess the duration of effects of ThermiTight.

## CONCLUSION

In this study, we evaluated the safety and clinical efficacy of a subsurface radiofrequency thermistor for nonsurgical treatment of the aging face in five patients. Patients and surgeons were satisfied with the clinical efficacy of the procedure. Complications are rare but possible for ThermiTight treatment of aging face.

## CONFLICT OF INTEREST

No conflicts of interest.

## FINANCIAL DISCLOSURE

No funding or financial support.

## BIBLIOGRAPHY

1. Dibernardo Be. The aging neck: a diagnostic approach to surgical and non-surgical options. *J Cosmet Laser Ther* 2013;14(2):56-64.

2. Mitz V, Peyronie M. The superficial musculo-aponeurotic system (SMAS) in the parotid and cheek area. *Plast Reconstr Surg* 1976;58(1):80–88.
3. Ahn DH, Mulholland RS, Diane D, Malcolm P. Non-excisional face and neck tightening using a novel subdermal radio-frequency thermo-coagulative device. *JCDSA* 2011;4(1):141–146.
4. Cheryl MB. Principles of soft tissue augmentation for the aging face. *Clin Interv Aging* 2006;1(4):349–355.
5. Camile H, Doris H, Manolea DP, Juliana S, Carolina S. Botulinum toxin type A for aging face and aesthetic uses. *Dermatol Ther* 2011;24(1):54–61.
6. Sadic N. Tissue tightening technologies: fact or fiction. *Aesthet Surg J* 2008; 28(2):180–188.
7. Lolis MS, Goldberg DJ. Radiofrequency in cosmetic dermatology: a review. *Dermatol Surg* 2012;38(11):1765–1776.
8. Alexiades-Armenakas M. Non-ablative skin tightening with a variable depth heating 1310 nm-wavelength laser in combination with surface cooling. *J Drugs Dermatol* 2007;6(11):1096–1103.
9. Key DJ. Comprehensive thermoregulation for the purpose of skin tightening using a novel radiofrequency treatment device. *J Drugs Dermatol* 2014; 13(2):185–189.
10. Alexiades-Armenakas M. A quantitative and comprehensive grading scale for rhytides, laxity, and photoaging. *J Drugs Dermatol* 2006;5(8):808–809.
11. Key DJ. Integration of thermal imaging with subsurface radiofrequency thermistor heating for the purpose of skin tightening and contour improvement: a retrospective review of clinical efficacy. *J Drugs Dermatol* 2014;13(12):1485–1489.
12. Lisa MD. Fat distribution: a morphologic study of the aging face. *Dermatol Surg* 2000;26(12):1107–1112.
13. Lin SJ, Hsiao CY, Sun Y, Lo W, Lin WC, Jan GJ, Jee SH, Dong CY Monitoring the thermally induced structural transitions of collagen by use of second-harmonic generation microscopy. *Oph Lett* 2005;30(6):622–624.
14. Mulholland RS. An in-depth examination of radiofrequency assisted liposuction (RFAL). *J Cosmet Surg Med* 2009;4(3):14–19.
15. Alster TS, Lupton JR. Nonablative cutaneous remodeling using radiofrequency devices. *Clin Dermatol* 2007;25(5):487–491.
16. Doherty CB, Doherty SD, Rosen T. Thermotherapy in dermatologic infections. *J Am Acad Dermatol* 2010;62(6):909–927.
17. Ikeda T, Tayefeh F, Sessler DI, et al. Local radiant heating increases subcutaneous oxygen tension. *Am J Surg* 1998;175(1):33–37.
18. Hutin Y, Hauri A, Chiarello L, Catlin M, Stilwell B, Ghebrehwet T, Garner J, Injection Safety Best Practices Development Group. Best infection control practices for intradermal, subcutaneous, and intramuscular needle injections *Bull World Health Org* 2003;81(7):491–500.