



ACTAS Derma-Sifiliográficas

Full English text available at
www.actasdermo.org



ORIGINAL

Platelet-Rich Plasma for the Treatment of Photodamage of the Skin of the Hands[☆]



J.O. Cabrera-Ramírez,^a A.G. Puebla-Mora,^b A. González-Ojeda,^c
D. García-Martínez,^c J.A. Cortés-Lares,^c A.R. Márquez-Valdéz,^c
G.I. Contreras-Hernández,^c J. Bracamontes-Blanco,^a J.A. Saucedo-Ortiz,^a
C. Fuentes-Orozco^{c,*}

^a Servicio de Cirugía Plástica, Hospital de Especialidades del Centro Médico Nacional de Occidente, Instituto Mexicano del Seguro Social, Guadalajara, Jalisco, Mexico

^b Servicio de Anatomía y Patología, Hospital de Especialidades del Centro Médico Nacional de Occidente, Instituto Mexicano del Seguro Social, Guadalajara, Jalisco, Mexico

^c Unidad de Investigación Biomédica 02, Unidad Médica de Alta Especialidad, Hospital de Especialidades, Centro Médico Nacional de Occidente, Instituto Mexicano del Seguro Social, Guadalajara, Jalisco, Mexico

Received 8 December 2016; accepted 18 April 2017

Available online 12 August 2017

KEYWORDS

Photodamage;
Platelet-rich plasma;
Growth factors

Abstract

Background: Platelet-rich plasma (PRP) provides growth factors that stimulate fibroblast activation and induce the synthesis of collagen and other components of the extracellular matrix. The objective of this study was to evaluate the effect of PRP in the treatment of photodamage of the skin of the hands.

Material and methods: Experimental study enrolling persons with photoaged skin on the dorsum of the hands (Glogau photoaging scale, type III, or Fitzpatrick wrinkle classification, type II) were included between August 2012 and January 2013. A histological comparison was made of skin biopsies taken before and after the application of PRP to the skin of the dorsum of the hands.

Results: The mean (SD) age of the 18 women enrolled was 47.9 (4.3) years. Histological analysis showed an increase in the number of fibroblasts ($P<.001$), number of vessels ($P<.001$), and collagen density ($P=.27$). These changes produced significant improvements in the Fitzpatrick wrinkle and elastosis scale ($P<.001$) and in the Glogau photoaging scale ($P=.01$).

[☆] Please cite this article as: Cabrera-Ramírez JO, Puebla-Mora AG, González-Ojeda A, García-Martínez D, Cortés-Lares JA, Márquez-Valdéz AR, et al. Plasma rico en plaquetas en el tratamiento del fotodaño cutáneo en las manos. Actas Dermosifiliogr. 2017;108:746–751.

* Corresponding author.

E-mail address: clotilde.fuentes@gmail.com (C. Fuentes-Orozco).

PALABRAS CLAVE

Fotodaño;
Plasma rico en
plaquetas;
Factores de
crecimiento

Conclusions: PRP induced a reduction in the manifestations of skin aging, including an improvement in wrinkles and elastosis.

© 2017 Elsevier España, S.L.U. and AEDV. All rights reserved.

Plasma rico en plaquetas en el tratamiento del fotodaño cutáneo en las manos

Resumen

Introducción: El plasma rico en plaquetas (PRP) aporta factores de crecimiento que inducen la síntesis de colágeno y otros componentes de la matriz extracelular, y estimula la activación de fibroblastos. El objetivo de este estudio es evaluar el efecto del PRP en el tratamiento del fotodaño en manos.

Material y métodos: Estudio de tipo experimental. Se incluyeron individuos con envejecimiento en el dorso de las manos, de tipo 3 en la escala de fotodaño de Glogau o de clase II de la clasificación de arrugas y elastosis de Fitzpatrick, entre agosto de 2012 y enero de 2013. Se aplicó PRP en la piel del dorso de las manos y se tomaron biopsias cutáneas antes y después del tratamiento para la comparación histológica.

Resultados: Se trataron 18 mujeres con una edad media de $47,9 \pm 4,3$ años. El análisis histológico demostró un incremento en el número de fibroblastos ($p = 0,000$), número de vasos ($p = 0,000$) y cantidad de colágeno ($p = 0,27$), representado como un cambio en la escala de clasificación de arrugas y elastosis de Fitzpatrick ($p < 0,001$) y en la escala de fotodaño de Glogau ($p = 0,01$).

Conclusiones: El PRP indujo una reducción en los signos y síntomas del envejecimiento cutáneo, con mejoría en las arrugas y elastosis.

© 2017 Elsevier España, S.L.U. y AEDV. Todos los derechos reservados.

Introduction

Skin aging is the result of accumulated damage that leads to the gradual biological and functional decline of cells over time (intrinsic aging) or the influence of environmental factors such as smoking, exposure to chemicals or UV radiation (extrinsic aging).¹

Constant exposure to UV radiation diminishes the structural function and integrity of the extracellular matrix through collagen degeneration and abnormal elastin structure, leading to the loss of both skin tone and elasticity, causing the signs of aging.²

Platelet activation in response to tissue damage and vascular exposure develops to promote hemostasis and secrete biologically active proteins³⁻⁶ that undertake functions related to chemotaxis, tissue proliferation and differentiation, angiogenesis, and regeneration of the extracellular matrix. A dose-response relationship between platelet concentration and the proliferation of mesenchymal cells, fibroblasts, and type 1 collagen has been observed in vitro.⁷⁻¹⁰

Growth factors in platelet-rich plasma (PRP) can stimulate fibroblast activation to regenerate damaged soft and hard tissues.^{2,3} These regenerative effects are attributed to the presence of biological factors such as platelet-derived growth factor, β -transforming growth factor, epidermal growth factor, insulin-like growth factor, and vascular endothelial growth factor, all of which are released locally after PRP is applied.¹¹ Increased dermal and epidermal thickness as well as enhanced numbers and organization of fibroblasts in photodamaged skin indicate that these factors

act on cell proliferation and reduce actinic elastosis^{12,13} even up to 3 months after application.⁶

Although PRP is used in a variety of conditions, only a few experimental studies have looked at the effects of PRP stimulation to treat skin aging.^{6,14-17}

Material and Methods

This experimental study was carried out between August 1, 2012, and January 31, 2013. After approval by the local medical research review board and ethics committee (file number R-2013-1301-142), we enrolled patients aged between 40 and 60 years who had mild skin photoaging according to the Glogau scale.¹⁸ The exclusion criteria were the use of topical treatments in the 6 months before the study, pregnancy, skin infection, a history of platelet dysfunction, use of corticosteroids, smoking, cancer, hemoglobin level less than 10 g/dL, or a platelet count less than $105 \times 10^9/L$.

Three PRP application sessions were given 30 days apart.

Outcomes were assessed on the Glogau scale and the Fitzpatrick wrinkle scale¹⁹ and through histologic examination of posttreatment skin biopsies. Patients were asked not to change their routine skin care habits during the study.

Method for Obtaining PRP

We extracted autologous venous blood into sterile vacuum collection tubes containing a solution of 3.2% sodium citrate. The tubes were then placed in a digital centrifuge

(MS 2000). The first cycle was set at 1500 rpm for 10 minutes to separate blood components (erythrocytes, buffy layer, and plasma). The plasma was then separated into 2 upper layers of platelet-poor plasma and a lower layer of PRP. Using sterile technique, we collected the 2 upper fractions from each patient sample into 2 sterile vacuum tubes using 10-mL syringes and 25-gauge, 16-mm hypodermic needles. The same procedure was then used to transfer each of the lower fractions to a third sterile vacuum tube for each sample. The 3 tubes containing the 3 plasma layers from each sample were then centrifuged at 2000 rpm for 10 minutes.²⁰

Anesthetic Technique

The dorsal surface of the hand was disinfected and an antiseptic solution was applied. Using sterile technique we performed radial and ulnar nerve blocks with subcutaneous injections of lidocaine in 2% solution. A total of 3 cc was injected proximal to the styloid apophysis of the radius (anatomical snuff box), and 2 cc was injected at the ulnar styloid apophysis between the flexor carpi ulnaris tendon and the ulnar artery.

Biopsy Method

We biopsied the most severely photodamaged area with a disposable 2.5-mm punch (Uni-Punch) at 2 moments: immediately before the first treatment application and 28 days after the last application.

PRP Application

The upper plasma fractions were activated by adding a 10:1 (10%) solution of calcium gluconate to the tube and shaking. The resulting mixture was extracted to a 100-IU syringe with a 25-gauge, 16-mm hypodermic needle. A No. 11 blade was used to make stab incisions on the dorsal surfaces of the second, third, and fourth interdigital spaces; 17-mm blunt-tipped catheters for lipids were inserted for radial and crossed-pattern injection of the plasma.^{21,22} Next, the lower fraction was activated in the same way, and injections of approximately 1.5 mL were made into the dermis from the dorsal surface of the hand with a 25-gauge, 16-mm needle. The injections were spaced 1.5 to 2 mm apart.

Clinical Evaluation

Participants were evaluated and classified on the Glogau photoaging scale¹⁸ before starting treatment and a month after the last application. The classifications were as follows: type I, early photoaging, no wrinkles; type II, early photoaging, appearance of wrinkles when skin moves; type III, advanced photoaging, wrinkles at rest; type IV, severe photoaging, wrinkles throughout. The patients were also evaluated on the Fitzpatrick wrinkle scale¹⁹ as class I, fine wrinkles and mild elastosis; class II, fine to moderately deep wrinkles and moderate elastosis; and class III, severe elastosis with fine to deep wrinkles.

Histology

Biopsied tissue samples were fixed with 10% formalin, sectioned (6 μ m), and stained with hematoxylin-eosin for fibroblasts and nuclei; Masson's trichrome for type I collagen fibers, and periodic acid-Schiff stain for basement membranes of blood vessels.

Digital images were taken and analyzed with Image software. Histologic assessment of blood vessels, collagen, and fibroblasts was performed on 10 fields, original magnification $\times 40$; the tissue examined was from a location 2 mm below the basement membrane of the epithelium (toward the deep dermis) in areas not adjacent to adnexa. Atypia, or fibroblastic reactivity in the nucleus, and elastosis were recorded as present or absent.

Statistical Analysis

Results for qualitative variables were described with absolute frequencies and percentages; they were compared with the Fisher exact test or the χ^2 test. Quantitative results were reported with mean (SD) and medians as appropriate; they were compared with the Wilcoxon signed-rank test. *P* values less than .05 were considered statistically significant.

Results

We included 20 women, 2 of whom interrupted treatment (1 because of isolated phlebitis of the arm and 1 because of uncontrolled dyslipidemia). The remaining 18 patients finished the study. The mean age was 47.9 (4.3) years.

The Fitzpatrick wrinkle scale evaluations improved significantly after the PRP treatments (*P* < .001). The mean pre- and posttreatment scores were 4.94 (0.80) and 2.78 (0.42), respectively, representing a change in category from class II to class I.

Eleven patients were initially classified as type III and 7 as type II according to the Glogau photaging scale. After treatment, 7 of the 11 patients (63.64%) were reclassified as type II (*P* = .01); the classification for the remaining patients did not change (Fig. 1).

On histologic assessment, we found increases in the number of blood vessels per standardized basement membrane measure and fibroblasts per number of nuclei examined. Papillary dermal collagen had also increased with treatments (Figs. 2 and 3).

We identified no changes in elastosis or basement membrane structure that could be attributed to PRP treatment, however. Nor did we find atypia in fibroblasts, other than vesicular nuclei and a few nucleoli in relation to slight fibroblastic reactivity.

The number of fibroblasts and blood vessels observed and the amount of collagen are shown in Table 1. Fibroblasts and blood vessels both increased.

Discussion

Skin shows the aging process through multiple clinical signs. One of the most important is the development of wrinkles, which gives the skin an undesirable appearance when

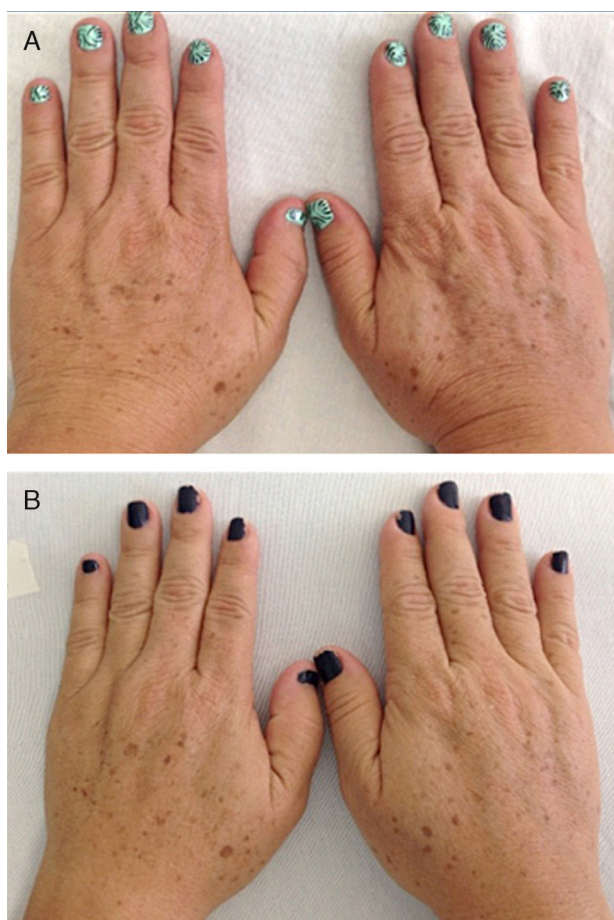


Figure 1 Dorsal surfaces of treated hands. A, Before treatments with platelet-rich plasma. B, After treatments.

combined with elastosis, color variations, and keratosis. Underlying these signs are histologic changes.

Several studies have shown that intradermal PRP injections can stimulate growth factors, favoring the regeneration of skin cells.^{23,24} We saw a considerable increase in the number of fibroblastic nuclei and augmentation of blood vessel basement membranes after PRP treatments. Although the assessed variables changed significantly, the increase in the amount of collagen present was not as marked as in some other studies.^{6,17}

In one of these studies, histology of skin biopsies after treatments with plasma rich in growth factors showed increased dermal and epidermal thickness and a significant increase in fibroblasts and collagen fibers 3 months after treatment ended.⁶ It is possible that the timing of the biopsy

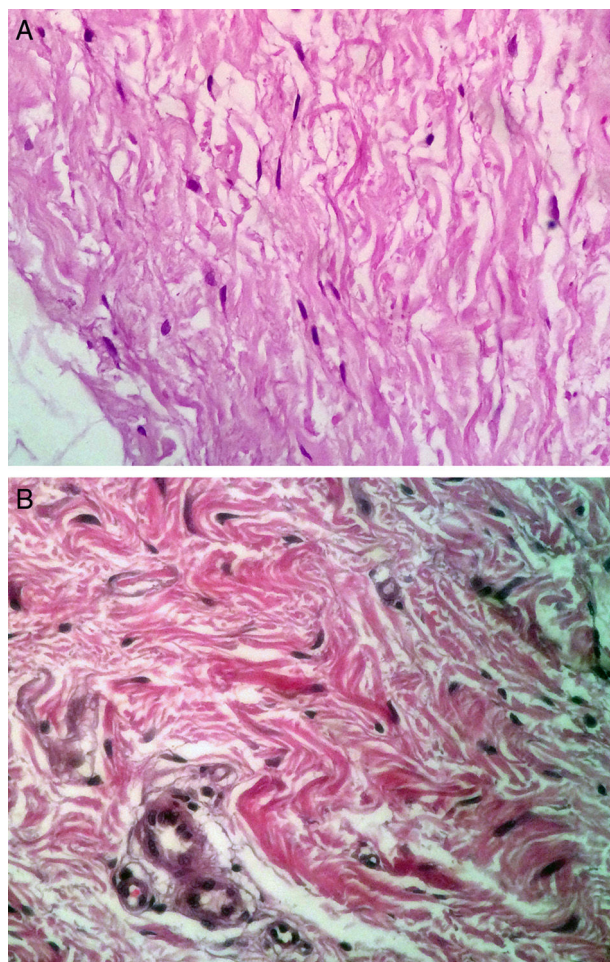


Figure 2 Histologic features of biopsied tissue; hematoxylin and eosin, original magnification $\times 40$. A, After treatments with platelet-rich plasma the number of fibroblasts increased. B, Before treatments.

may affect whether histologic changes can be visualized or not. However, our findings were consistent with a study in which patients reported a change in the severity of wrinkles in spite of the lack of a significant increase in the amount of collagen.²⁵

Fibroblasts are responsible for synthesizing the reticular, collagen, and elastic fibers of the extracellular matrix of tissues; thus, stimulating the production of fibroblasts will enhance the matrix.^{26,27} We therefore believe that the processes of tissue repair and regeneration will continue to take place in our patients beyond the moment when we took our measurements. Histologic changes would probably

Table 1 Histologic Findings Before and After Platelet-Rich Plasma Treatments.

	Before Treatments			After Treatments			Z Score	P ^a
	No.	Mean (SD)	Median	No.	Mean (SD)	Median		
Fibroblasts/250 μm^2	18	2.78 (0.42)	3	18	4.94 (0.80)	5	-3.77	.000
Mean fraction of the area with collagen	18	60.67 (2.78)	62	18	63 (1.60)	63	-2.20	.27
No. of blood vessels/250 μm^2	18	6.72 (1.80)	6.5	18	11.5 (2.3)	11.5	-3.49	.000

^a Wilcoxon signed-rank test.

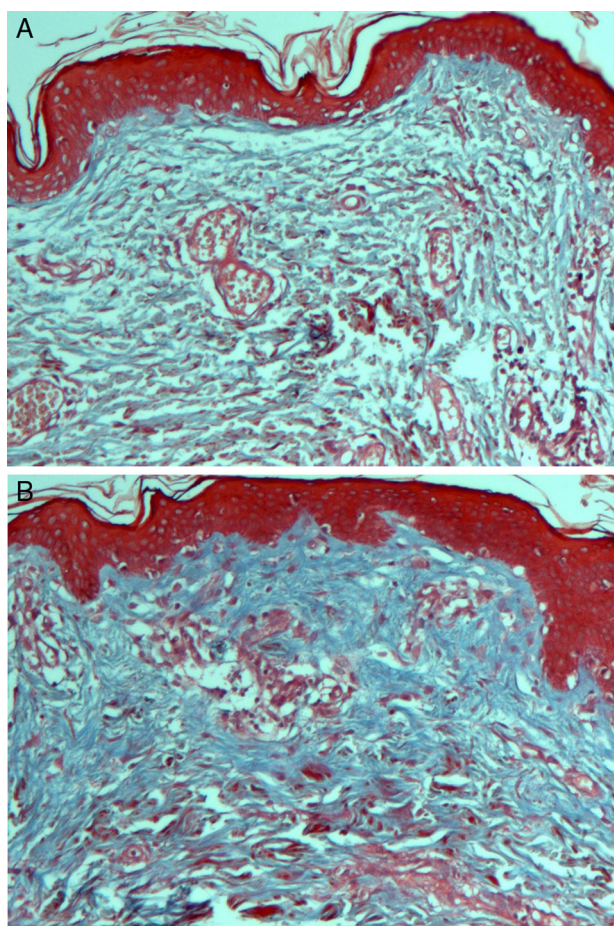


Figure 3 Collagen fibers; Masson's trichrome, original magnification $\times 40$. A, Before treatments with platelet-rich plasma. B, After treatments collagen had increased.

have become significantly more evident in later biopsies. The early timing of the biopsy procedures in our study was therefore a limitation.

The proangiogenic factors released by PRP also promote a change in endothelial cell phenotype, favoring proliferation and enabling cells to remodel the extracellular matrix of circulating blood, as well as migrate to the focus of angiogenesis and differentiate to form new blood vessels.^{8,28} Cell lines responsible for angiogenesis are also involved in the recognition, repair, and chemotaxis required for regeneration. Angiogenesis could therefore be critical for sustaining the clinical effects of PRP treatment. We suggest that angiogenesis should be assessed in future clinical trials.

Some authors have found that topical or subcutaneous application of PRP and growth factors lead to significant changes in the skin.^{29,30} These treatments restore elasticity and vitality as well as increase thickness and enhance blood flow, suggesting that PRP and growth factors regulate dermal and epidermal remodeling in facial skin. However, the fact that the mere use of a needle to inject any substance might in itself activate fibroblasts in the skin and stimulate collagen synthesis was mentioned in one study.³ Abuaf et al.¹⁷ recently showed that the amount of collagen increased with mesotherapy even without the application of PRP. It would be reasonable, therefore, to expect that our

study would demonstrate even greater changes, given the technique we used; we did not see a large effect, however.

Because the hands are generally under repeated exposure to sunlight, our findings may be useful for deciding how to treat photodamaged skin in areas that are less exposed. Our review of the literature indicates that this is the first study on the effect of hand skin rejuvenation through PRP treatments. We believe that more such studies should be done to further our understanding of the effects of applying PRP to photodamaged skin.

Conclusion

PRP treatments reduced signs of skin aging, favored collagen synthesis, and increased the number of fibroblasts and blood vessels in the superficial layer of the dermis.

Ethical Disclosures

Protection of human and animal subjects. The authors declare that the procedures followed adhered to the ethical guidelines of the responsible committee on human experimentation and comply with the Declaration of Helsinki of the World Medical Association.

Data confidentiality. The authors declare that they followed their hospitals' regulations regarding the publication of patient information and that written informed consent for voluntary participation was obtained for all patients.

Right to privacy and informed consent. The authors have obtained the informed consent of the patients and/or subjects referred to in this article. The signed forms are in the possession of the corresponding author.

Conflicts of Interest

The authors declare that they have no conflicts of interest.

References

1. Yaar M, Eller MS, Gilchrist BA. Fifty years of skin aging. *J Invest Dermatol Symposium Proceedings*. 2002;7:51–8.
2. Sclafani AP. Applications of platelet-rich fibrin matrix in facial plastic surgery. *Facial Plast Surg*. 2009;25:270–6.
3. Kim DH, Je YJ, Kim CD, Lee YH, Seo YJ, Lee JH, et al. Can platelet-rich plasma be used for skin rejuvenation? Evaluation of effects of platelet-rich plasma on human dermal fibroblast. *Ann Dermatol*. 2011;23:424–31.
4. Anitua E, Sanchez M, Orive G, Andía I. The potential impact of the preparation rich in growth factors (PRGF) in different medical fields. *Biomaterials*. 2007;28:4551–60.
5. Leo MS, Kumar AS, Kirit R, Konathan R, Sivamani RK. Systematic review of the use of platelet-rich plasma in aesthetic dermatology. *J Cosmet Dermatol*. 2015;14:315–23.
6. Díaz-Ley B, Cuevas J, Alonso-Castro L, Calvo MI, Ríos-Buceta L, Orive G, et al. Benefits of plasma rich in growth factors (PRGF) in skin photodamage: Clinical response and histological assessment. *Dermatol Ther*. 2015;28:258–63.
7. Online Archive of International cellular medicine society. Section VIII Platelet rich plasma (PRP) guidelines 2011 [cited 2014 Oct 3]. Available from:

- [http://www.cellmedicinesociety.org/attachments/370.Section%2010%20-%20Platelet%20Rich%20Plasma%20\(PRP\)%20Guide%20lines.pdf](http://www.cellmedicinesociety.org/attachments/370.Section%2010%20-%20Platelet%20Rich%20Plasma%20(PRP)%20Guide%20lines.pdf).
8. Anitua E. The use of plasma-rich growth factors (PRGF) in oral surgery. *Pract Proced Aesthet Dent*. 2001;13:487–93.
 9. Beca T, Hernández G, Morante S, Bascones A. Plasma rico en plaquetas; una revisión bibliográfica. *Av Periodon Implantol*. 2007;19:39–52.
 10. Henderson J, Cupp C, Ross E, Shick P, Keefe M, Wester D, et al. The effects of autologous platelet gel on wound healing. *Ear Nose Throat J*. 2003;82:598–602.
 11. Shin M, Lee J, Lee S, Kim N. Platelet-rich plasma combined with fractional laser therapy for skin rejuvenation. *Dermatol Surg*. 2012;38:623–30.
 12. Li Z, Choi H, Choi D, Sohn K, Im M, Seo Y, et al. Autologous platelet-rich plasma: A potential therapeutic tool for promoting hair growth. *Dermatol Surg*. 2012;38:1040–6.
 13. Rabe J, Mamelak A, McElgunn P, Morison W, Sauder D. Photoaging, mechanisms and repair. *J Am Acad Dermatol*. 2006;55:1–13.
 14. Bhanot S, Alex JC. Current applications of platelet gels in facial plastic surgery. *Facial Plast Surg*. 2002;18:27–33.
 15. Yao E, Eriksson E. Gene therapy in wound repair and regeneration. *Wound Repair Regen*. 2000;8:4443–51.
 16. Escobar HM. Terapia de bioestimulación con plasma rico en plaquetas para el envejecimiento cutáneo. *Rev Argent Dermatol*. 2012;93.
 17. Abuaf OK, Yildiz H, Baloglu H, Bilgili ME, Simsek HA, Dogan B. Histologic evidence of new collagen formulation using platelet rich plasma in skin rejuvenation: A prospective controlled clinical study. *Ann Dermatol*. 2016;28:718–24.
 18. Glogau RG. Aesthetic and anatomic analysis of the aging skin. *Semin Cutan Med Surg*. 1996;15:134–8.
 19. Fitzpatrick RE, Goldman MP, Satur NM, Tope WD. Pulsed carbon dioxide laser resurfacing of photo-aged facial skin. *Arch Dermatol*. 1996;132:395–402.
 20. Perez AG, Lana JFS, Rodrigues AA, Luzo ACM, Belangero WD, Santana MHA. Relevant aspects of centrifugation step in the preparation of platelet-rich plasma. *ISRN Hematol*. 2014.
 21. Butterwick KJ. Lipoaugmentation for aging hands: A comparison of the longevity and aesthetic results of centrifuged versus noncentrifuged fat. *Dermatol Surg*. 2002;28:987–91.
 22. Coleman SR. Hand rejuvenation with structural fat grafting. *Plast Reconstr Surg*. 2002;110:1731–44.
 23. Kakudo N, Minakata T, Mitsui T, Kushida S, Notodihardjo FZ, Kusumoto K. Proliferation-promoting effect of platelet-rich plasma on human adipose-derived stem cells and human dermal fibroblasts. *Plast Reconstr Surg*. 2008;11:1352–60.
 24. Carrillo P, Gonzalez A, Macias S. Plasma rico en plaquetas ¿Herramienta versátil de la medicina regenerativa? *Cir Cir*. 2013;81:74–82.
 25. Elnehrawy NY, Ibrahim ZA, Eltoukhy AM, Nagy HM. Assessment of the efficacy and safety of single platelet-rich plasma injection on different types and grades of facial wrinkles. *J Cosmet Dermatol*. 2016, <http://dx.doi.org/10.1111/jocd.12258>.
 26. Lacci K, Dardik A. Platelet-rich plasma: Support for its use in wound healing. *Yale J Biol Med*. 2010;83:1–9.
 27. Arquero P. Plasma rico en plaquetas en cirugía estética. *Cir Estet Plas*. 2009;5:42–8.
 28. Fitzpatrick RE, Rostan EF. Reversal of photodamage with topical growth factors: A pilot study. *J Cosmet Laser Ther*. 2003;5:25e34.
 29. Ehrlich M, Rao J, Pabby A, Goldman MP. Improvement in the appearance of wrinkles with topical transforming growth factor beta and 1-ascorbic acid. *Dermatol Surg*. 2006;32:618–25.
 30. Gold MH, Goldman MP, Biron J. Efficacy of novel skin cream containing mixture of human growth factors. *J Drugs Dermatol*. 2007;6:197–201.