

# Follicular Unit Transplantation

Daniel E. Rousso, M.D., F.A.C.S.,<sup>1</sup> and Paul M. Presti, M.D.<sup>2</sup>

## ABSTRACT

Follicular unit transplantation (FUT) is the culmination of decades of refinement and evolution of hair transplantation techniques. Hair naturally grows in groups of one to four individual follicles separated by intervening soft tissue. These clumps or groups of hairs are termed *follicular units*. FUT uses microscopic dissection to separate these units for transplantation in a fashion that most closely resembles naturally occurring hair. FUT has grown to become recognized by many prominent hair restoration surgeons as the state-of-the-art method of hair replacement surgery for both male and female pattern alopecia. Although larger punch grafts, scalp flaps, and alopecia reductions may play a role in certain cases, FUT achieves results that are difficult to differentiate from naturally occurring hair. The central attributes of the technique are the provision of natural-appearing hairlines with reasonable density together with low morbidity and minimal “downtime.” Nevertheless, the technique is only as effective as the technician, and results are heavily dependent on the forethought of the architect.

**KEYWORDS:** Follicular unit transplantation, FUT, hair transplantation, alopecia, male pattern hair loss, female pattern hair loss, male pattern alopecia, female pattern alopecia

Hair replacement surgery has experienced a dramatic and rapid evolution since the inception of the large punch graft nearly 50 years ago. Many techniques have been introduced and some abandoned in an attempt to achieve improved efficiency and, more importantly, better outcomes. In our quest to achieve progressively more natural results, we have moved toward smaller and smaller grafts. Follicular unit transplantation (FUT) is the culmination of decades of refinement of hair transplantation techniques. FUT allows us to achieve superior results with minimized morbidity and is considered by many prominent hair surgeons to be the state-of-the-art method for the treatment of both male and female pattern alopecia. This review provides a description of the concepts that structure the surgery and details the technique and practice of the authors.

## HISTORY

Conceivably, one could trace the concept of hair auto-transplantation back to the early 19th century. J. Dieffenbach, a German doctoral student working on his final thesis, demonstrated the feasibility of autologous transfer of hair, skin, and feathers in fowl and animals. The information was not further used until the mid-20th century. Although there existed several accounts of punch grafts used by a Japanese physician, Okuda, to treat alopecia in burn victims, the first person credited for using grafting to treat male pattern baldness was Dr. Norman Orentreich.<sup>1,2</sup> His publication in the *Annals of the New York Academy of Science* in 1959 marked the inception of hair restoration surgery and dubbed him as its founding father. Other notable surgeons in the field (H. Sturm, S. Ayres, P. Rabineau, among others)

<sup>1</sup>Rousso Facial Plastic Surgery Clinic, Birmingham, Alabama; <sup>2</sup>Private Practice, Westfield, New Jersey.

Address for correspondence and reprint requests: Daniel E. Rousso, M.D., F.A.C.S., Rousso Facial Plastic Surgery Clinic, 2700 Highway 280, Suite 300, West Wing, Birmingham, AL 35223 (e-mail: drousso@aol.com).

Hair Restoration; Guest Editor, Daniel E. Rousso, M.D., F.A.C.S.

Facial Plast Surg 2008;24:381-388. Copyright © 2008 by Thieme Medical Publishers, Inc., 333 Seventh Avenue, New York, NY 10001, USA. Tel: +1(212) 584-4662.

DOI 10.1055/s-0028-1102902. ISSN 0736-6825.

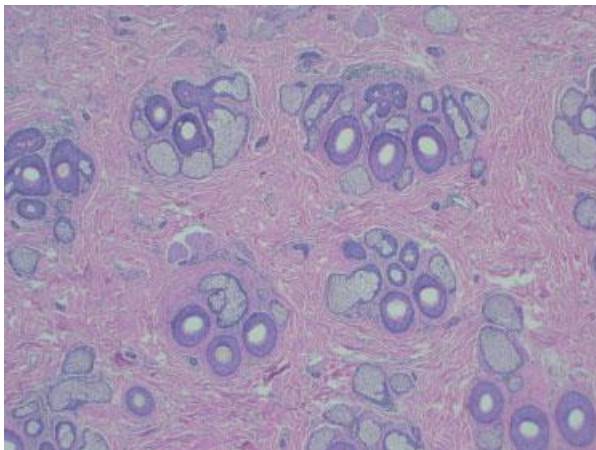
benefited from the dissemination of information and tutelage of Dr. Orentreich.

The practice of the time, using 4-mm punch grafts, though effective, left many searching for alternative techniques that would produce more “natural” appearing results. Ultimately, this would take the form of progressively higher numbers of smaller grafts. The basic science behind the feasibility of smaller grafts was borne out of the work of J.T. Headington.<sup>3</sup> He is credited with describing the *follicular unit* as an anatomic entity. Thereafter, the technique of follicular unit dissection and transfer was defined and progressively honed.


## THEORY AND ANATOMY

Previously, hair transplantation commonly consisted of transfer of *micrografts* (one to two hairs) and *minigrafts* (three to five hairs), which were defined by size and hair number. The process has evolved, however, with insight to the anatomic arrangement of hair. The follicular unit is thought of as the fundamental unit of hair transplantation. To better explain the concept, one must define a *microfollicular unit*. The unit is composed of one to four terminal hair follicles, (with or without several vellus follicles), associated sebaceous glands, a common vascular and neural plexus, surrounded by a connective tissue sheath. These follicular bundles are evident when a segment of hair-bearing scalp is evaluated under microscopic visualization (Fig. 1). What are readily apparent are the small groupings of several terminal hairs with a relatively large area of surrounding non-hair-bearing skin (Fig. 2).

It would follow that harvesting and transferring individual follicular units would minimize the transplantation of “excess” non-hair-bearing tissue and, moreover, allow a high-density re-creation of the natural distribution of hair. The need to create large recipient sites as with minigrafts is obviated, thereby minimizing trauma to the recipient bed. This has been demonstrated



**Figure 1** Follicular units composed of one to four terminal hairs, associated sebaceous glands, and erector pili muscle, surrounded by connective tissue (Hematoxylin-eosin,  $\times 25$ ).



**Figure 2** Follicular units exiting scalp.

in practice and has provided for a more natural result. Although other techniques such as micrografts and even punch grafts have merits and clear applications, use of FUT has been described as the state of the art.

Logically, the follicular unit should not be further divided lest one decrease the likelihood of graft survival.<sup>4</sup> Yet there is conflicting data as to the veracity of this logic.<sup>5,6</sup> It is not clear whether or not division of the follicular units into single subunit grafts affects outcome.

The density of follicular units (number of follicular units [FU] per  $\text{mm}^2$ ) within the scalp varies with location. The midoccipital area is the most dense, followed by the midmastoid area and the supraauricular area. On average in Caucasians, the density of the scalp is 1 FU/ $\text{mm}^2$  ( $\sim 175$  to  $275$  hairs/ $\text{cm}^2$  or 80 to 120 FU/ $\text{cm}^2$ ).<sup>7</sup> The occipital scalp relative density and its resistance to the hormone-related alopecia make it the preferred donor site for grafts.

## PATIENT SELECTION

Choosing the “right” patient is crucial to the final success of any hair transplant technique. There are few true absolute contraindications to the surgery, and the facility of making that determination relies on the physician’s experience. An allergy to lidocaine, active autoimmune disease, and a health status inadequate to undergo a surgical procedure of this degree notwithstanding, most patients qualify to undergo hair transplantation. However, there are characteristics that make certain patients more suitable than others.

Much thought is given to the age of a potential patient. Our experience has demonstrated that patients under the age of 25 years tend to be less content with any results that may be gained by hair transplant surgery. This sentiment has been echoed in the experience of other institutions.<sup>8</sup> The reason for this observation is likely multifold. Younger patients tend to have unrealistic expectation of the density they can expect after surgery. Moreover, patients who develop premature alopecia will have more hair loss over the ensuing years

such that any gain with surgery may be less impressive. Finally, younger patients have not yet fully realized the degree of alopecia that they will ultimately have and often expect to regain the full, thick hair that they recently possessed. There is also the risk of hypertrophic scarring that can afflict younger patients. Hair density, color, texture, and scalp laxity also play important roles in identifying appropriate candidates for surgery. Evaluating for occipital scalp laxity will determine if graft harvest is reasonable, especially in patients who have undergone transplantation in the past. Failure to note this preoperatively can lead to untoward healing due to excessive wound tension. The occipital hair density will similarly play a determining role. The density of the occipital hair dictates the number of grafts that can be harvested at an individual session. The patient with less than desirable density may not qualify for “total” scalp coverage but may be a suitable candidate for creating a frontal hairline. Even a patient with relatively poor density may be suitable for an isolated frontal forelock.

The apparent density of the scalp after transplantation varies with characteristics of the implanted hair. Coarse, curly hair appears denser than fine, straight hair. Likewise, light hair against a background of light skin appears denser as does dark hair with dark scalp skin.

During the initial consultation, all of these factors are thoroughly reviewed with the patient so that realistic expectations are realized. Medical treatments including finasteride and minoxidil are also presented as potential adjuvants.

## TECHNIQUE

Although there are many idiosyncratic nuances to an individual’s technique in hair transplant surgery (i.e., type of knife used, technique employed to implant grafts, the type of microscope used to dissect follicular units), the fundamentals of the process and maintaining the integrity of individual follicular units during the process are relatively standard. Our technique is outlined herein.

## Preoperative Events

On the day of surgery, once a thorough review of the patient’s medical history and a brief focused exam are performed, a second consultation is undertaken with the patient. At this time, a detailed review of the design of the transplantation is discussed with a focus on the thought behind the design and reasonable expectations. The proposed hairline is drawn on the patient’s head and agreed upon by both the patient and the surgeon.

## Anesthesia

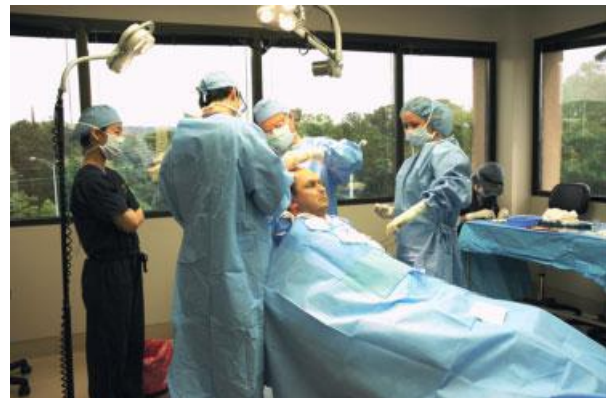It is our practice to provide a preoperative sedative 30 minutes prior to injection of local anesthesia. Typi-

cally, this entails 10 to 20 mg of oral diazepam depending on the patient’s habitus and experience of benzodiazepines. The anxiolytic effect along with its mild amnestic and sedative qualities provides for an easier transition to the operating area and improves patient comfort during the injection of local anesthesia. Diazepam also raises the seizure threshold for lidocaine toxicity and adds further protection from this possible complication. The local anesthesia is then infiltrated. Two percent lidocaine with 1:100,000 epinephrine is used to perform supra-orbital, occipital, and postauricular nerve blocks that precede a ring block via 1% lidocaine with 1:100,000 epinephrine. Attention is paid to the quantity of lidocaine infused to ensure not to exceed the maximum dosage. The scalp is then addressed with subdermal infusion of 1% lidocaine with 1:100,000 epinephrine.

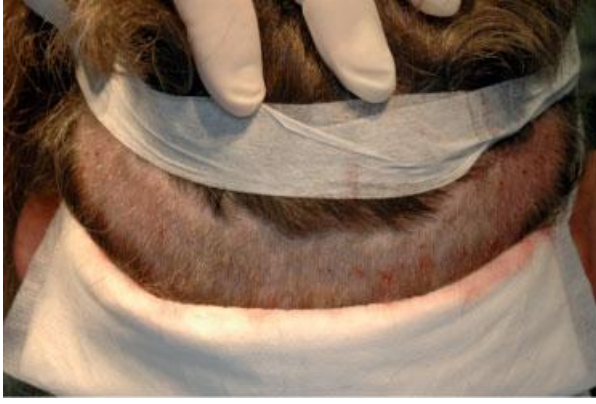During the procedure, as bleeding is encountered with the creation of recipient sites and graft placement, small aliquots (~0.1 mL) of “superjuice” (1% lidocaine with 1:50,000 epinephrine) are infused for hemostasis.

## Staffing

To maximize efficiency, we use a two-team approach wherein the surgeon and technician work simultaneously. The strip is harvested and passed off to a team (typically two to three trained technicians) responsible for slivering and preparing the microfollicular units while the surgeon creates the recipient sites. Thereafter, one or two of the technicians begin implanting the grafts (Fig. 3), and the remaining technicians continue processing the strips into follicular unit transplants. Using this method, a large session transplant (1100 to 1800 total grafts) can be performed typically in 5 hours. The duration of the procedure, however, is variable as the size of the team performing the surgery is only a small component in the multitude of determining factors. Clearly, the skill and experience of each operator as well as the difficulty of an individual case (i.e., gray or light hair, short curled hair, the presence of scar tissue, excessive bleeding/graft popping) plays a significant role



**Figure 3** Office operating suite.

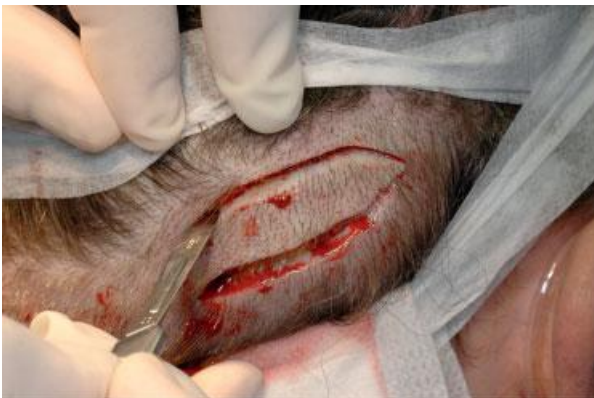

**Figure 4** Donor area trimmed and taped for exposure.

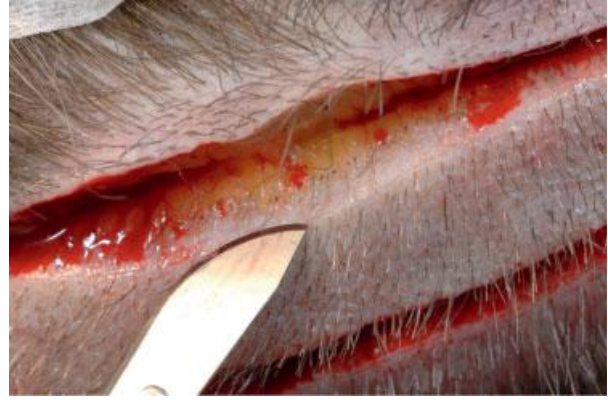in determining the amount of time needed for a case and the number of team members required.

### Graft Harvest

Successful harvest of a strip of dense hair-bearing occipital scalp is the sine qua non of FUT. The density of the occipital scalp hair can be measured objectively with densitometers, video microphotography, or by the estimation of an experienced transplant surgeon. As previously mentioned, this determination is performed preoperatively. The proposed donor area is determined and trimmed with scissors to leave a small (2 mm) stub of hair exiting the scalp. This remaining stub aids in the determination of the angle the hair exits the scalp and will be crucial in avoiding transection of the follicles during removal of the donor strip. The hair is parted superior and inferior to the midoccipital harvest site with circumferential tape (Fig. 4). The planned scalp excision extends in a horizontal fashion, overlying the densest area of occipital and (if needed) parietal scalp. Typically, the dimensions of the harvested graft approximate 18 cm (length) by 1 to 1.5 cm (width) during a large session transplant. This size of strip is usually sufficient to yield 1100 to 1800 microfollicular units, depending on the density of the donor scalp.



**Figure 5** Donor incisions.



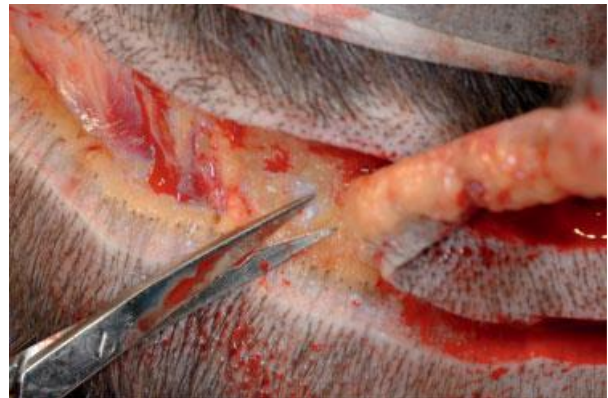**Figure 6** Donor incisions.

A key element of the harvest is the creation of beveled incisions (Figs. 5 and 6). The superior incision should parallel the direction of the hair follicles to minimize destruction of follicular units. The inferior incision is “overbeveled” to leave deepithelialized follicles on the inferior side of the inferior incision, thereby creating a trichophytic closure and facilitating the growth of hair through the resultant scar. The strip is then sharply dissected in a deep subcutaneous plane, below the hair follicles and immediately above the plane of the occipital arteries and nerves (Fig. 7).

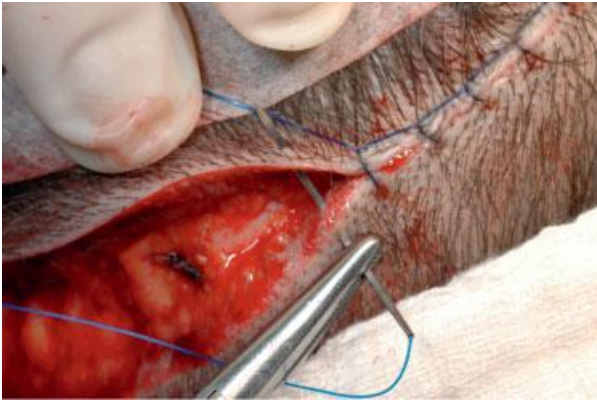
Closure of the wound is performed with a running locking 2-0 Prolene suture (Ethicon Inc., Somerville, NJ) using small, intradermal “bites” of the cut edge of the scalp without undermining the surrounding tissues (Fig. 8). Multiple different closure techniques have been attempted, and our experience has delivered the best results with the aforementioned (Fig. 9).

### Slivering and Preparation of Microfollicular Units

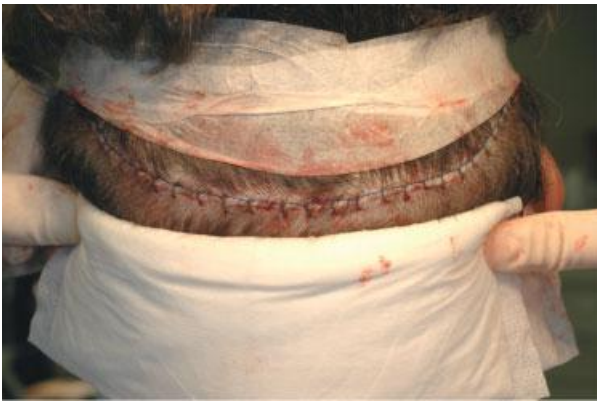The harvested strip is passed to the members of the team designated for preparation of the microfollicular units. Throughout this process and until placement, the grafts must remain moist. They are constantly bathed with



**Figure 7** Donor strip is carefully removed.

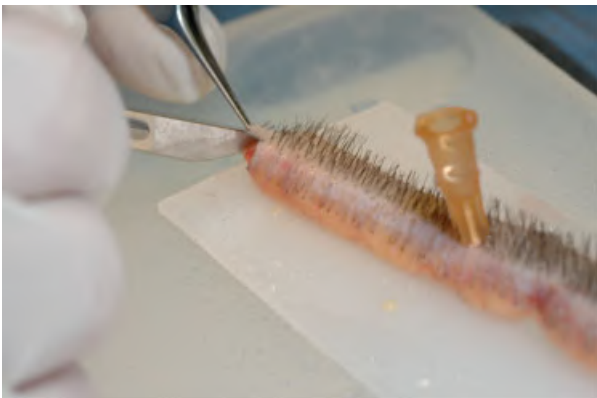

**Figure 8** Suture closure of donor defect.

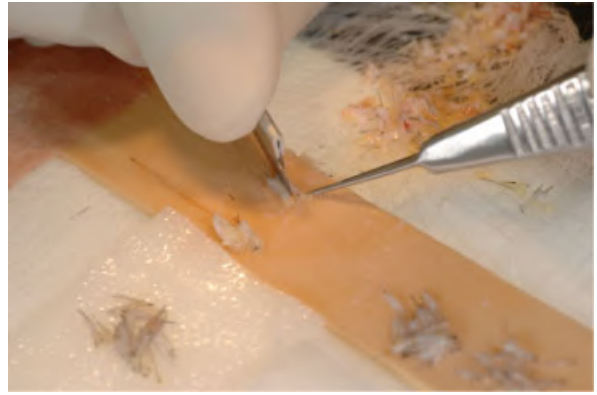

**Figure 9** Wound closed.

saline-soaked nonadherent (Telfa) gauze (Kendall Co., Mansfield, MA). The initial phase of this process is sharp dissection of the grafts into single-follicular-unit-thick slivers that are easier to manage (Fig. 10). Each sliver is then sharply dissected into microfollicular units (Figs. 11 and 12). These procedures are performed under a stereoscopic binocular microscope to preserve the integrity of the follicular unit (Fig. 13). The grafts are separated into aggregates of 100 grafts, which are then passed on to a team member assigned to implantation.



**Figure 10** Strip is cut into slivers.

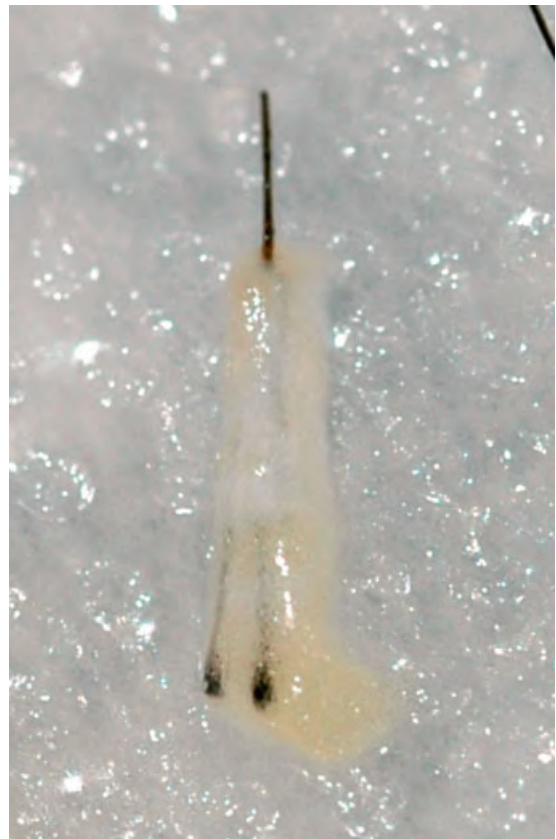

**Figure 11** Slivers are dissected into follicular unit transplants.

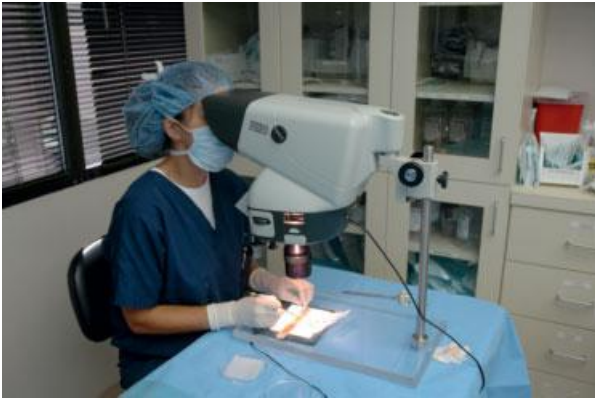### Recipient Graft Site Creation

Our preference is to create all of the intended recipient sites prior to initiating implantation. We use a 1.3-mm Minde knife with a 40-degree-angle blade (Surgical Specialties Inc., San Juan, Puerto Rico) to create precise, minute stab incisions for the grafts (Fig. 14).

The angle at which each site is created is of particular significance because it will influence hair growth. Direction should be determined by the natural arrangement of the scalp hair. For example, the frontal hairline usually emerges acutely with the scalp almost



**Figure 12** Close up of follicular unit transplant (FUT).



**Figure 13** Mantis (Vision Engineering, New Milford, CT) dissecting microscope.

parallel to the ground whereas the temple hairline is directed directly down (Fig. 14).

Essentially, one must approximate with high fidelity the natural, current pattern of hair direction to obtain a “natural-appearing” result.

**Implantation**

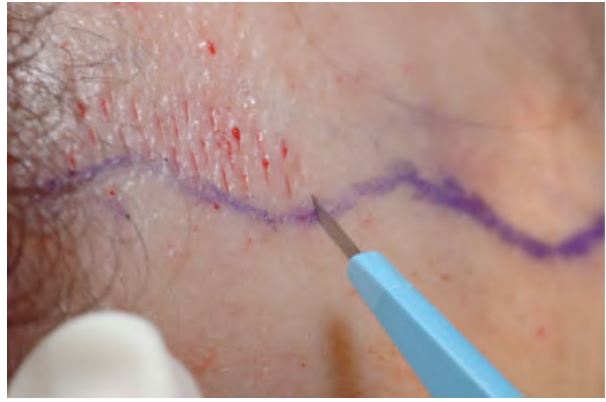The graft recipient sites are cleared of coagulated blood and debris with a spray of one-half hydrogen peroxide solution. The grafts are then meticulously placed with fine jewelers forceps (Fig. 15).

**Postoperative Instructions**

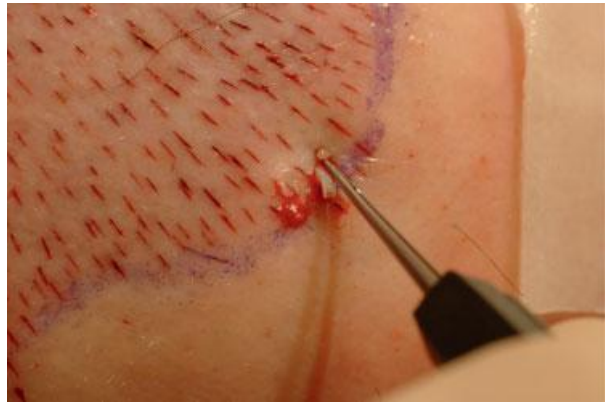
Patients are discharged the same day after applying antibiotic ointment and a protective nonadherent pad (Telfa). On postoperative day 1, patients shower and carefully rinse their scalp with water only. Thereafter, they are instructed to use a spray bottle to apply witch hazel 4 to 5 times per day to facilitate the debridement of typical crusting that forms around the graft sites. Two days after the surgery, the hair can be rinsed with a mild “baby” shampoo. The patients typically return on postoperative day 7 for suture removal.



**Figure 14** Minge knife.



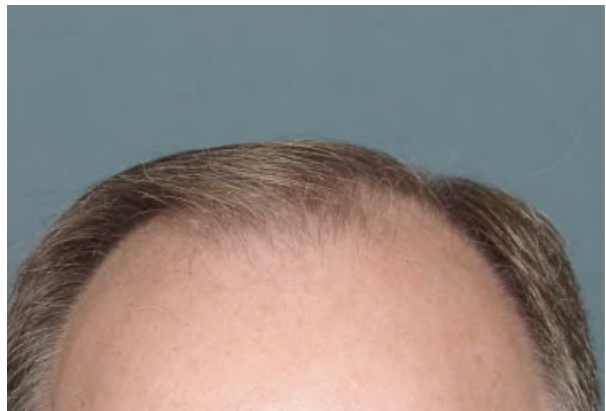
**Figure 15** Creating recipient sites.



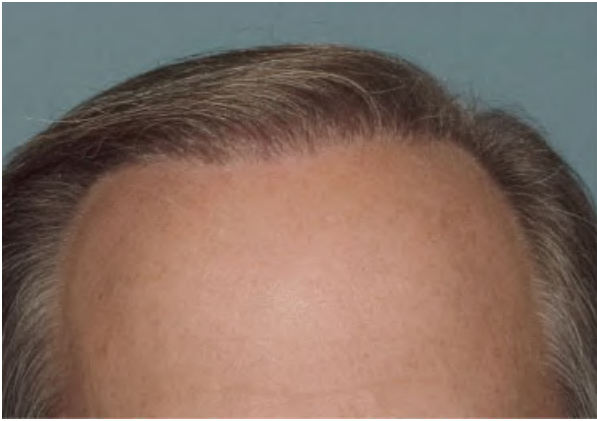**Figure 16** Placing follicular unit transplant grafts.

**RESULTS**

As with any hair transplants, FUT hair will begin to grow approximately 3 to 4 months after the procedure. Initially, the new hair will be delicate and fine, however, as the hair grows longer, it will become more coarse. Ultimately, the hair will achieve the same quality as the donor area from which it was harvested. Most patients will require 2–3 stages of transplants to achieve the



**Figure 17** Patient A: preoperative view.

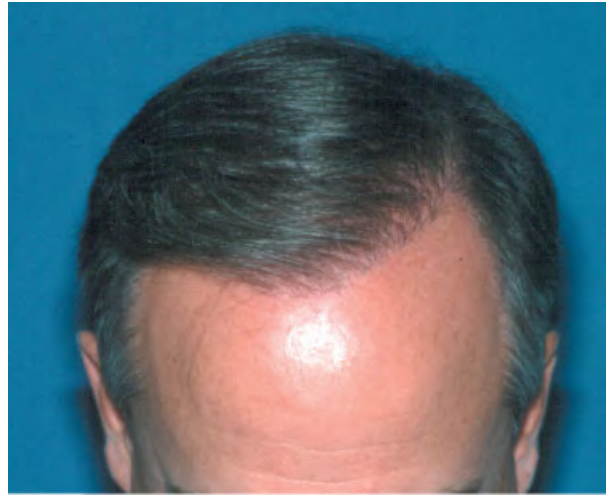


**Figure 18** Patient A after three sessions of 1200 follicular unit transplants, for a total of 3600 FUT.

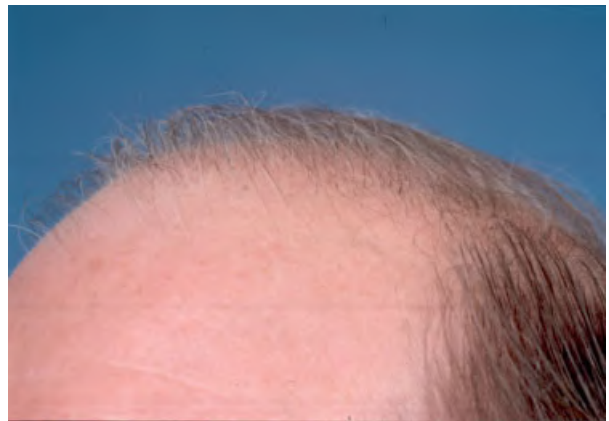desired final density. Subsequent stages can be performed as early as 6 months apart. Patient A received three sessions of FUT (Figs. 17–20). Each session was 1200 FUT grafts, done at one year intervals, for a total of 3600 FUT grafts. Patient B also received three sessions of FUT grafts (Figs. 21 and 22). The initial session was 1000 FUT grafts, followed by two subsequent stages of 1200 FUT grafts for a total of 3400 FUT grafts. FUT grafting can yield excellent results that are virtually indistinguishable from naturally growing hair.

### CONCLUSION

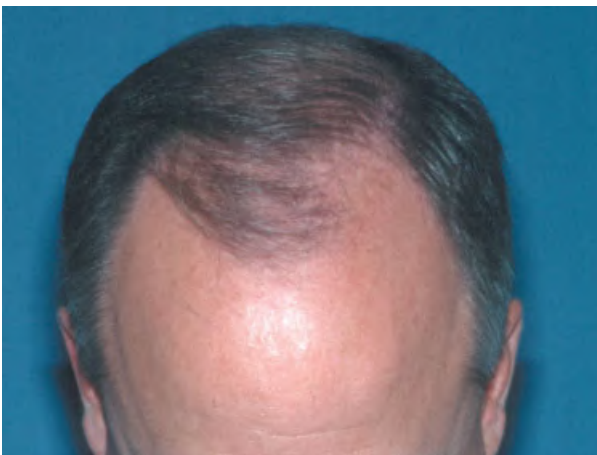Transplantation of individual follicular units can provide for natural-appearing results while optimizing the density of scalp hair. The underlying principle is that non-hair-bearing skin, which comprised ~50% of the scalp, is not transferred along with the individual follicular units. The graft survival is predicated on the meticulous preservation of each unit during every step



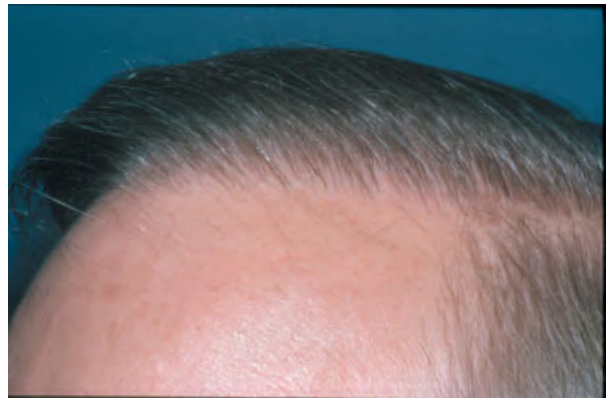**Figure 20** Patient A after three sessions each of 1200 follicular unit transplants, for a total of 3600 FUT.



**Figure 21** Patient B: preoperative view.



**Figure 19** Patient A: preoperative view.



**Figure 22** Patient B after one session using 1000 FUT and two sessions of 1200 follicular unit transplants, for a total of 3400 FUT.

of the process and the skillful harvest of donor grafts. With strict adherence to these fundamental principles and appropriate patient selection, our experience has shown a high rate of patient satisfaction with low associated morbidity.

## REFERENCES

1. Orentreich N. Autografts in alopecias and other selected dermatological conditions. *Ann N Y Acad Sci* 1959;83:463–479
2. Okuda S. [Clinical and experimental studies of transplantation of living hairs]. *Jpn J Dermatol Urol* 1939;46:135–138
3. Headington JT. Transverse microscopic anatomy of the human scalp: a basis for a morphometric approach to disorders of the hair follicle. *Arch Dermatol* 1984;120:449–456
4. Unger WP, ed. *Hair Transplantation*. New York, NY: Informa Healthcare; 2005:389
5. Seager D. Binocular stereoscopic dissecting microscopes: should we use them? *Hair Transplant Forum Int* 1996;6:2–5
6. Limmer BL. Elliptical donor stereoscopically assisted micrografting as an approach to further refinement in hair transplantation. *J Dermatol Surg Oncol* 1994;20:789–793
7. Bernstein RM, Rassman WR. Follicular unit transplantation: 2005. *Dermatol Clin* 2005;23:393–414
8. Brandy DA. An evaluation system to enhance patient selection for alopecia-reducing surgery. *Dermatol Surg* 2002;28:808–816